Tianjin Daxue Xuebao (Ziran Kexue yu Gongcheng Jishu Ban)/
Journal of Tianjin University Science and Technology
ISSN (Online):0493-2137
E-Publication: Online Open Access
Vol: 59 Issue: 11:2026
DOI: 10.5281/zenodo.24104259

THE IMPACT OF STICKY BONE GAP AUGMENTATION ON BUCCAL BONE PRESERVATION AFTER IMMEDIATE IMPLANTS IN MAXILLARY SINGLE ROOTED TEETH: A RANDOMIZED CONTROLLED CLINICAL TRIAL

ALSHAIMA ADEL AHMED TANTAWY*

Department of Oral and Maxillofacial Surgery Faculty of Dentistry, Suez Canal University, Ismailia, Egypt.
*Corresponding Author Email: shaimat254@gmail.com

AHMED HOSSAM ELDIN

Department of Oral and Maxillofacial Surgery Faculty of Dentistry, October University for Modern Sciences and Arts, 6 October City, Egypt.

SW ARAFAT

Department of Oral and Maxillofacial Surgery Faculty of Dentistry, October University for Modern Sciences and Arts, 6 October City, Egypt.

MOHAMED AHMED ELSHOLKAMY

Department of Oral and Maxillofacial Surgery Faculty of Dentistry, Suez Canal University, Ismailia, Egypt.

Abstract

Introduction: Immediate implant placement reduces treatment time and preserves prosthetic outcomes but often leaves a peri-implant "jumping gap" between implant and buccal socket wall. The need to graft this gap remains controversial. This randomized study assessed whether filling the peri-implant gap with sticky bone improves hard-tissue preservation and implant stability for single-rooted maxillary teeth. Materials and **methods:** Thirteen patients (16 implants; age 20-43 years) requiring extraction of single-rooted maxillary anterior or premolar teeth were randomized into two equal groups. Group 1 (control) received immediate implants without grafting (n = 8); Group 2 (study) received immediate implants with sticky bone grafting of jumping gaps ≥2 mm (n = 8). ROOTT implants (10-12 mm length; 3.5-4.2 mm diameter) were placed following a standardized surgical protocol. Clinical assessment and CBCT were performed immediately and at 6 months. Outcomes included buccal bone width (at 2, 4, 6 mm levels), crestal bone loss, CBCT-derived bone density (NewTom Giano HR), and implant stability (Osstell ISQ). Statistical analysis used Shapiro–Wilk, independent-samples t tests, and paired-samples t tests ($\alpha = 0.05$). **Results:** All implants survived at 6 months (100% survival). Grafted sites showed a significant increase in buccal bone width (mean change +33.7%) versus significant reduction in controls (-25.9%; $P < 0.001$). Crestal bone loss was greater in control than grafted sites ($P = 0.007$). Bone density and ISQ increased significantly over time in both groups but did not differ between groups in 6 months. **Conclusion:** Within 6 months, sticky bone grafting of peri-implant gaps during immediate implant placement preserved buccal contours and reduced marginal bone loss. Larger, longer-term studies with histologic evaluation are recommended.

Keywords: Immediate Dental Implants, Sticky Bone, Buccal Bone Preservation, Cone-Beam Computed Tomography (CBCT), Implant Stability (ISQ).

Tianjin Daxue Xuebao (Ziran Kexue yu Gongcheng Jishu Ban)/
Journal of Tianjin University Science and Technology
ISSN (Online):0493-2137
E-Publication: Online Open Access
Vol: 59 Issue: 11:2026
DOI: 10.5281/zenodo.24104259

INTRODUCTION

Dental implantology has become a reliable and widely accepted method for restoring missing teeth, offering outcomes that closely mimic natural dentition. Post-extraction alveolar bone remodeling commonly leads to reductions in ridge height and width, complicating subsequent surgical and restorative procedures (Atwood and Coy, 1971; Misch et al., 2005). Immediate implant placement first reported with osseointegrated implants by Schulte et al. in 1978 (Schultz AJ., 1993) has shown high survival rates when implants are placed into well-selected extraction sockets and confers advantages such as fewer surgical interventions, faster recovery, and improved aesthetics (Henry and Liddelow, 2008). However, immediate placement may be contraindicated in cases of significant infection, ankylosis, buccal plate fracture, or socket enlargement, and presents challenges in achieving primary stability and optimal implant positioning (Bhola et al., 2008). Biologic events at the bone–implant interface involve a cascade of cellular and molecular processes haematoma formation, recruitment and activation of osteogenic cells, woven bone formation, and subsequent lamellar bone remodeling culminating in osseointegration (Mavrogenis et al., 2009; Babu and Ogle, 2015). Successful osseointegration depends on multiple factors including implant material and surface properties, implant design and primary stability, the condition of the implant bed, surgical technique, and an undisturbed healing period (Ryu et al., 2014; Sales et al., 2023). Resonance frequency analysis (RFA) and devices such as Osstell ISQ provide noninvasive, reproducible measures of implant stability and correlate positively with bone–implant contact (Meredith et al., 1998; Herrero-Climent et al., 2013; Kastala, 2018). Extraction socket healing is characterized by substantial dimensional change, particularly within the first six months to two years post-extraction, with reported mean horizontal and vertical bone losses (Van Weijden et al., 2009; Tan et al., 2012; Udeabor et al., 2023). Immediate implant placement can mitigate alveolar ridge resorption, but buccal bone remodeling especially the resorption of the bundle bone remains a concern (Araújo et al., 2015). Critical site- and procedure-dependent factors influencing outcomes include buccal plate thickness, socket size, gap dimension (jumping distance), flap versus flapless approaches, implant positioning, and the use of bone or connective tissue grafts (Liñares et al., 2023; Naiem et al., 2024). The concept of the “jumping gap” denotes the horizontal and vertical peri-implant void between the palatally positioned implant and the facial socket wall. Evidence suggests that gaps larger than 2 mm may benefit from grafting and barrier materials to maintain hard and soft tissue architecture (Kabi et al., 2020). Bone augmentation is frequently required in the anterior maxilla, where buccal defects are common due to trauma or pathology. Various graft materials autografts, allografts, xenografts, and alloplasts are used, each with advantages and limitations; autografts remain the gold standard but are limited by donor morbidity (Wu et al., 2019; Mavrogenis et al., 2009). Xenografts and bone substitutes have shown effectiveness in preserving ridge dimensions when used to fill the peri-implant gap (Araújo et al., 2015; Groenendijk et al., 2017). Recently, “sticky bone” a growth factor–enriched graft matrix prepared with autologous fibrin glue has been proposed to stabilize particulate grafts, reduce graft micromotion, and enhance healing in peri-implant defects (Mohammed,

Tianjin Daxue Xuebao (Ziran Kexue yu Gongcheng Jishu Ban)/
Journal of Tianjin University Science and Technology
ISSN (Online):0493-2137
E-Publication: Online Open Access
Vol: 59 Issue: 11:2026
DOI: 10.5281/zenodo.24104259

2020; Sareen et al., 2024a). Cone-beam computed tomography (CBCT) offers three-dimensional preoperative assessment of bone quality and morphology with lower cost and radiation than conventional CT, aiding accurate planning for immediate implant procedures (Naitoh et al., 2010; Yiğit Özer, 2011). Given the ongoing debate about management of small peri-implant defects, this study aims to evaluate grafting the peri-implant gap around immediate implants for single-rooted maxillary teeth, assessing effects on stability and hard-tissue preservation. The current study aimed at clinical and radiographic evaluation of grafting the peri-implant gap around immediate implants for restoring single rooted maxillary teeth.

MATERIALS AND METHODS

This study comprised 16 immediate implants placed in 13 patients who required extraction of maxillary single-rooted anterior or premolar teeth. Patients were recruited from the outpatient clinic of the Oral and Maxillofacial Surgery Department, Faculty of Dentistry, Suez Canal University. Ages ranged from 20 to 43 years; six males and seven females were included. The protocol followed the principles of the Declaration of Helsinki and all participants provided written informed consent.

Inclusion and Exclusion Criteria:

Patients over 18 years with non-restorable single-rooted maxillary anterior or premolar teeth indicated for extraction and single-implant replacement were considered. Only sites with intact extraction sockets and at least 3 mm of bone beyond the socket apex to ensure primary stability were included. Participants were required to demonstrate adequate oral hygiene and agree to perform regular home dental care. Exclusion criteria were untreated rampant caries or uncontrolled periodontal disease, systemic conditions contraindicating surgery or impairing bone healing, periapical lesions at the extraction site, heavy smoking, alcohol abuse, parafunctional habits, and pregnancy or lactation.

Patient Grouping and Randomization:

After medical and dental history collection via written questionnaire and clinical examination, patients received periodontal therapy (scaling and/or root planing) and oral hygiene instruction. Following atraumatic extraction and socket assessment, eligible sites were randomized into two equal groups using Research Randomizer (https://www.randomizer.org/). Group 1 (control) comprised eight immediate implants placed without grafting. Group 2 (study) comprised eight immediate implants placed with grafting of the peri-implant jumping gap using sticky bone.

Implants and Grafting Material:

A total of 16 ROOTT implants with lengths of 10-12 mm and diameters of 3.5–4.2 mm was used in the 13 patients. ROOTT implants feature a V-shaped design, variable threads for bone condensation, and a neck range starting at 2.05 mm with screw-retained prosthetic options; the system is described as having no micro-gap/no micromovement (Fig. 1).

Tianjin Daxue Xuebao (Ziran Kexue yu Gongcheng Jishu Ban)/
Journal of Tianjin University Science and Technology
ISSN (Online):0493-2137
E-Publication: Online Open Access
Vol: 59 Issue: 11:2026
DOI: 10.5281/zenodo.24104259



A B

Figure 1: Clinical Pictures Showing A: ROOTT Implant, B: Implant's V-Shape and Sharp Threads

The grafting material used was sticky bone (S1), a bovine cancellous xenograft predominantly composed of hydroxyapatite (HA). Sticky bone was prepared by hydrating the xenograft with autologous blood or saline to produce a moldable, cohesive graft that can be shaped and placed into the peri-implant defect; the material's interconnected pore structure promotes new bone ingrowth (Fig. 2).



Figure 2: Clinical Pictures Showing S1, A: Bovine Cancellous Bone Xenograft With HA (Hydroxyapatite), B: S1 Mixed With Saline to Form Sticky Bone

Preoperative Assessment:

All patients underwent comprehensive clinical and radiographic evaluation. Preoperative clinical assessment included occlusion, intermaxillary relationship, mucosal status, and oral hygiene instruction. Patients were instructed to use chlorhexidine gluconate 0.12% mouthwash four times daily for one week preoperatively. Panoramic radiographs and preoperative cone-beam computed tomography (CBCT) scans were obtained for all patients to assess bone quantity/quality beyond the root apices and to plan implant length and diameter (Fig. 3). Data was recorded on individual patient questionnaires and clinical charts.

Tianjin Daxue Xuebao (Ziran Kexue yu Gongcheng Jishu Ban)/
Journal of Tianjin University Science and Technology
ISSN (Online):0493-2137
E-Publication: Online Open Access
Vol: 59 Issue: 11:2026
DOI: 10.5281/zenodo.24104259



Figure 3: Preoperative Panoramic X-Ray to Identify Any Periapical Lesions

Surgical Protocol:

A standardized surgical protocol was followed for all cases. Patients received a single oral dose of amoxicillin–clavulanate (Augmentin) 1 g one hour before surgery and performed a one-minute rinse with chlorhexidine 0.12% immediately prior to the procedure . The perioral skin was disinfected with 10% povidone-iodine. Local anesthesia was achieved using Articaine HCl 4% with epinephrine 1:100,000 via buccal and palatal para-periosteal infiltration .Atraumatic extraction was performed with periotomes to preserve gingival and osseous tissues. Sockets were curetted and irrigated with saline; integrity of buccal and lingual plates was confirmed by inspection and palpation. A full-thickness mucoperiosteal flap was elevated with a No. 15 scalpel blade to expose the buccal bone. The implant osteotomy was positioned approximately one-third along the palatal wall from the apex to avoid buccal dehiscence and oriented using adjacent teeth and cortical plates as guides. Osteotomy preparation used the manufacturer's surgical kit. Pilot drilling was performed to the planned depth at 1,200–2,500 rpm depending on bone density under continuous saline irrigation. Drilling technique included a pumping motion with irrigation flow of 40–100 ml/min to avoid overheating. Torque settings were adjusted between 30 and 50 Ncm. Sequential widening drills to the predetermined depth matched implant diameters. Implants were seated using a hex tool and torque wrench to place the implant approximately 2 mm subcrestal relative to the buccal plate, anchoring into the apical alveolar bone to achieve primary stability. For group allocation, the buccal jumping gap between implant and buccal plate was measured; sites with gaps ≥2 mm was included and grafted with sticky bone in the study group only. Sticky bones were prepared by the chairside by hydrating the xenograft with blood or saline, molding it to fill the jumping gap, and placing it around the implant.

Primary Stability and Closure:

Primary implant stability (T0) was measured intraoperatively using the Osstell ISQ system with SmartPeg transducers; resonance frequency analysis provided Implant Stability

Tianjin Daxue Xuebao (Ziran Kexue yu Gongcheng Jishu Ban)/
Journal of Tianjin University Science and Technology
ISSN (Online):0493-2137
E-Publication: Online Open Access
Vol: 59 Issue: 11:2026
DOI: 10.5281/zenodo.24104259

Quotient (ISQ) values. A cover screw was placed, and a tension-free primary mucosal closure was achieved using 3-0 non-absorbable sutures (Fig. 4-7).

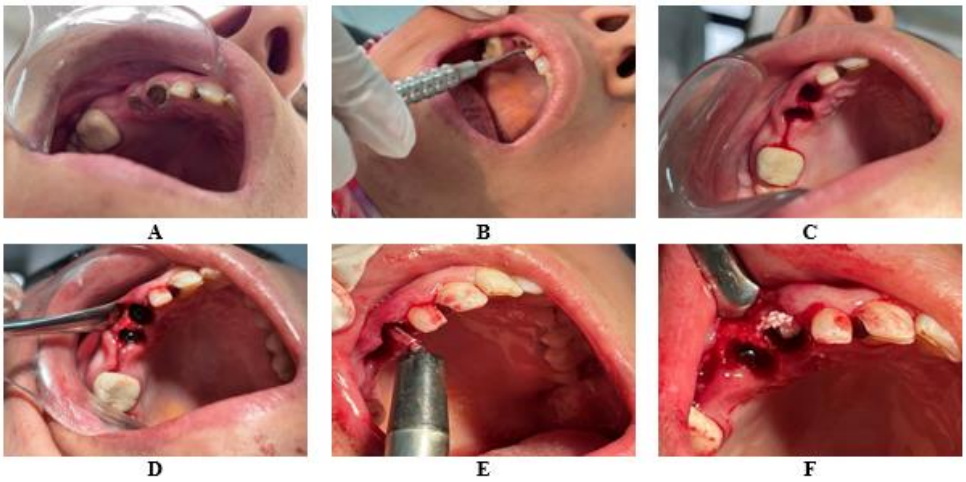

Figure 4: Surgical Procedure of Patient No.8 Group2. A: Badly Decayed Upper Canine And First Premolar. B: Atraumatic Extraction Using Periotome. C: Examination of Empty Socket after Extraction. D: Placement of Implants in the Sockets. E: Immediate Postoperative Stability Measurement Using Osstell. F: Placing Sticky Bone in the Peri-Implant Gap

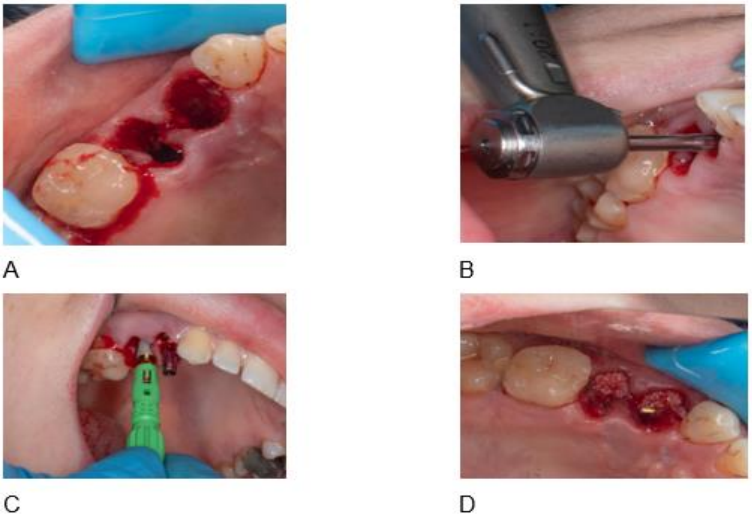

Figure 5: Surgical Procedure of Patient No. 12 Group2, a: Examination of Empty Socket after Extraction, B: Osteotomy in Upper First Premolar. C: Implant Insertion in Second Premolar. D: Bone Graft Using Sticky Bone in Peri-Implant Gap

Tianjin Daxue Xuebao (Ziran Kexue yu Gongcheng Jishu Ban)/
Journal of Tianjin University Science and Technology
ISSN (Online):0493-2137
E-Publication: Online Open Access
Vol: 59 Issue: 11:2026
DOI: 10.5281/zenodo.24104259

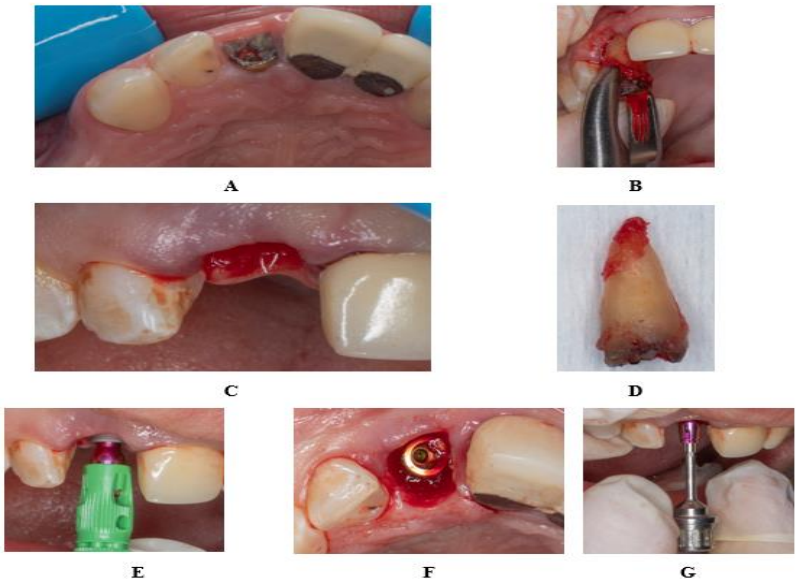

Figure 6: Surgical Procedure of Patient No.4 Group1. A: Badly Decayed Upper Right Lateral, B: Clinical Picture Showing Atraumatic Extraction Using Anterior Forceps, C: Picture Showing Intact Papilla And Empty Socket, D: Intact Upper Lateral Incisor, E: Implant Insertion, F: Implant Completely Seated In the Socket, G: Abutment Insertion Using Screw Driver

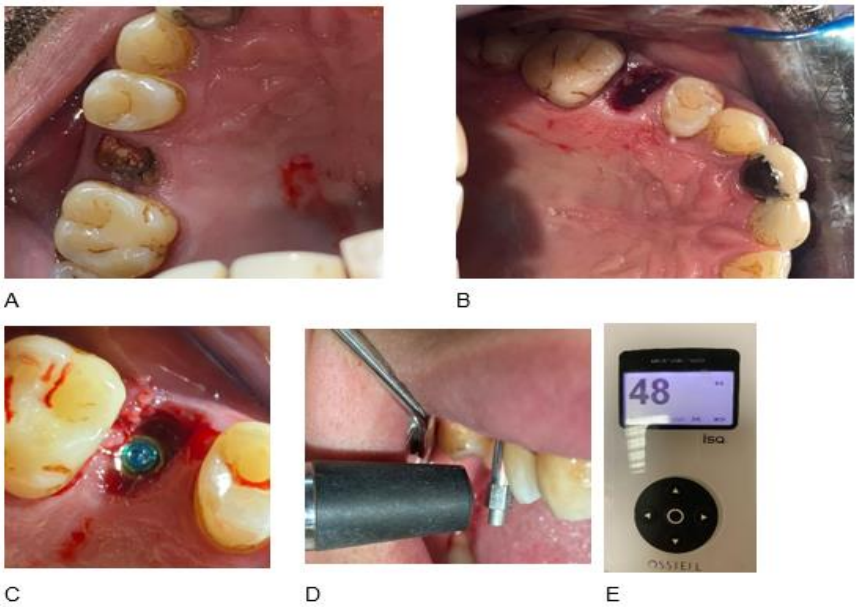

Figure 7: Surgical Procedure of Patient No.6 Group 1. A: Badly Decayed Upper Left Second Premolar, B: Fresh Socket, C: Complete Implant Insertion in the Socket, D: Immediate Postoperative Stability Measurement Using Smart Peg and Osstell Device. E: Osstell Device

Tianjin Daxue Xuebao (Ziran Kexue yu Gongcheng Jishu Ban)/
Journal of Tianjin University Science and Technology
ISSN (Online):0493-2137
E-Publication: Online Open Access
Vol: 59 Issue: 11:2026
DOI: 10.5281/zenodo.24104259

Postoperative Care:

Immediate postoperative care included intermittent facial cold packs for 6 hours, antiseptic mouthwash (Antiseptol) after meals for one week starting 24 hours post-op, and warm saline rinses beginning the day after surgery for 10 days. Normal oral hygiene resumed on day 2. Patients were reviewed at 24 hours and sutures were removed at 7 days. Postoperative medications included Augmentin 1 g every 12 hours for 6 days and ibuprofen (Brufen) 400 mg every 8 hours for 3 days.

Follow-Up and Outcomes:

Clinical and radiographic evaluations were performed immediately and at 6 months postoperatively. Implant stability was reassessed at 6 months using Osstell RFA. CBCT imaging was acquired one week and six months after surgery. Bone density measurements used NewTom Giano HR viewer software gray-scale values, recorded by a single blinded calibrated examiner. Buccal bone thickness was measured on CBCT from the implant shoulder at 2, 4, and 6 mm levels perpendicular to the implant long axis (Fig. 8, Fig. 9). Crestal bone level was measured as the distance from alveolar crest to implant collar immediately and at 6 months; the difference provided crestal bone loss.



Figure 8: CBCT picture showing bone density measurements



Figure 9: CBCT picture showing buccal bone thickness measurements

Statistical Analysis:

Data normality was assessed by Shapiro–Wilk test. Descriptive statistics are reported as mean ± SD. Independent-samples t-test compared between groups and paired-samples t-test assessed changes over time. A two-sided $P \leq 0.05$ was considered statistically significant. Analyses were performed using IBM SPSS for Windows, version 26.0.

RESULT

Demographic Table:

The age of the current study population, the extracted teeth, and the implant dimensions are presented in table 1. The patients were selected from the Out-patient clinic of Oral

Tianjin Daxue Xuebao (Ziran Kexue yu Gongcheng Jishu Ban)/
Journal of Tianjin University Science and Technology
ISSN (Online):0493-2137
E-Publication: Online Open Access
Vol: 59 Issue: 11:2026
DOI: 10.5281/zenodo.24104259

and Maxillofacial Surgery Department, Faculty of Dentistry, Suez Canal University. The participants were randomized into 2 groups: Group 1 and Group 2. Group 1 (the control group) included 7 patients (5 males and 2 females), while group 2 (the study group), also had 6 patients (1 male and 5 females). Their age ranged from 20-43 years with mean age of 24.4 years.

Table 1: Demographic Data of the Control and Study Groups

Group	Patient no.	Implant no.	Age (years)	Sex	Extracted Tooth	Implant
1 (control)	1	1	26	Male	Right central incisor	3.8*12
	2	2	25	Male	Right 2nd premolar	4.2*12
	3	3	32	Female	Left lateral incisor	3.5*12
	4	4	23	Male	Right lateral incisor	3.8*10
	5	5	29	Male	Right 1st premolar	4.2*12
		6			Right 2nd premolar	4.2*12
	6	7	35	Male	Left 2nd premolar	4.2*10
	7	8	33	Female	Left canine	3.8*14
2 (study)	8	9	35	Female	Right canine	3.5*14
		10			Right 1st premolar	3.8*12
	9	11	28	Female	Left lateral incisor	3.5*10
	10	12	32	Female	Left 2nd premolar	4.2*14
	11	13	36	Female	Right 1st premolar	4.2*12
	12	14	28	Female	Right 1st premolar	4.2*12
		15			Right 2nd premolar	4.2*12
	13	16	29	Male	Left central incisor	3.5*10

Surgical Outcomes

The surgical procedure was generally well tolerated. All implants showed healthy peri-implant soft tissue except for two implants (implant no. 2 group 1, implant no. 10 group 2) showed peri-implantitis during the early follow up period. This was successfully managed by chlorohexidine mouth wash and by the end of the study these implants showed healthy peri-implant soft tissue. By the end of the study, none of the implants showed clinical mobility. All subjects completed the 6-month follow up examination. No implants were lost during this observation period yielding a 6-month survival rate of 100%.

Statistical Analysis:

All data calculated, tabulated, and statistically analyzed using suitable statistical tests as follows. A normality test (Shapiro-Wilk) was done to check the normal distribution of the samples. Descriptive statistics were calculated in the form of Mean ± Standard deviation (SD)

- Independent sample T test was used to compare between two different groups.
- Paired samples T test was used to compare between different time intervals (at immediate and 6 months).
- P value ≤ 0.05 is considered statistically significant.

Tianjin Daxue Xuebao (Ziran Kexue yu Gongcheng Jishu Ban)/
Journal of Tianjin University Science and Technology
ISSN (Online):0493-2137
E-Publication: Online Open Access
Vol: 59 Issue: 11:2026
DOI: 10.5281/zenodo.24104259

- Statistical analysis was performed using the computer program SPSS software for windows version 26.0 (Statistical Package for Social Science, Armonk, NY: IBM Corp) at significant levels<0.05 (P- Value).

1- Buccal bone width

Mean and Standard deviation (SD) value for Buccal bone width in Group 1 (G1) and Group 2 (G2) were presented in Table (2) and figure (10).

Table 2: Mean and Standard Deviation (SD) Value for Buccal Bone Width in Both Groups

	G1		G2		Independent T test	P value
	Mean	SD	Mean	SD		
Immediate	1.836	0.031	1.855	0.042	1.018	0.326
6 Months	1.360	0.324	2.480	0.099	9.344	<0.001**
% change	-25.9		33.7			
Paired T test	4.207		25.00			
P value	0.004**		<0.001**			
****, means significant difference at P<0.01**						

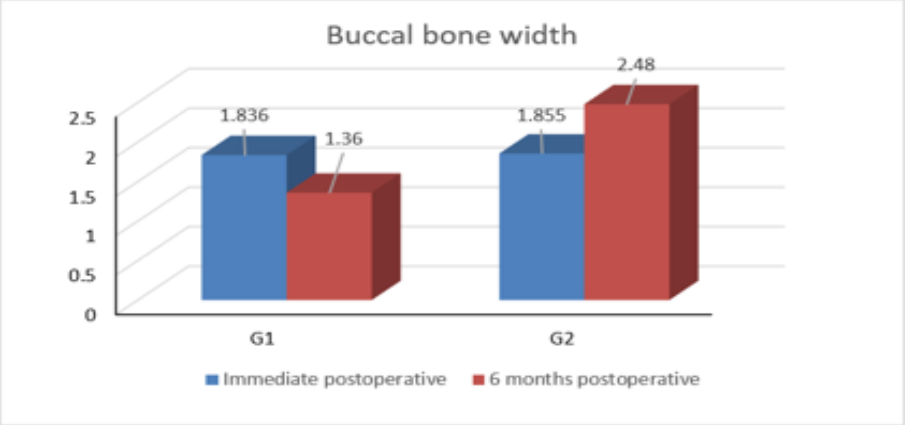

Figure 10: Graph Showing the Buccal Bone Width for both Groups Immediately and 6 Months Postoperatively

A-Intergroup Comparisons:

There was statistically significant difference between G1 and G2 regarding Buccal bone width either in immediate, and after 6 months, the mean values was higher in G2 (1.855±0.042) and (2.480±0.099) compared with (1.836±0.031) and (1.360±0.324) at immediate, and after 6 months respectively.

B-Intragroup Comparisons:

For G1, there was a significant reduction in mean value of Buccal bone width measured at 6 months (p=0.004) while for G2 there was a significant increase in mean value (P<0.001) after 6 months with significant change 25.9% and 33.7% respectively.

Tianjin Daxue Xuebao (Ziran Kexue yu Gongcheng Jishu Ban)/
Journal of Tianjin University Science and Technology
ISSN (Online):0493-2137
E-Publication: Online Open Access
Vol: 59 Issue: 11:2026
DOI: 10.5281/zenodo.24104259

2-Crestal bone loss

Mean and Standard deviation (SD) value for crestal bone loss in G1 and G2 were presented in Table (3) and figure (11).

Table 3: Mean and Standard Deviation (SD) Value for Crestal Bone Loss in Both Groups

	G1		G2		Independent T test	P value
	Mean	SD	Mean	SD		
Immediate	0.525	0.149	0.600	0.107	1.158	0.266
6 Months	1.250	0.193	0.988	0.136	3.151	0.007
% change	138.1		64.6			
Paired T test	29.00		5.594			
P value	<0.001**		0.001**			
****,** means significant difference at P<0.01						

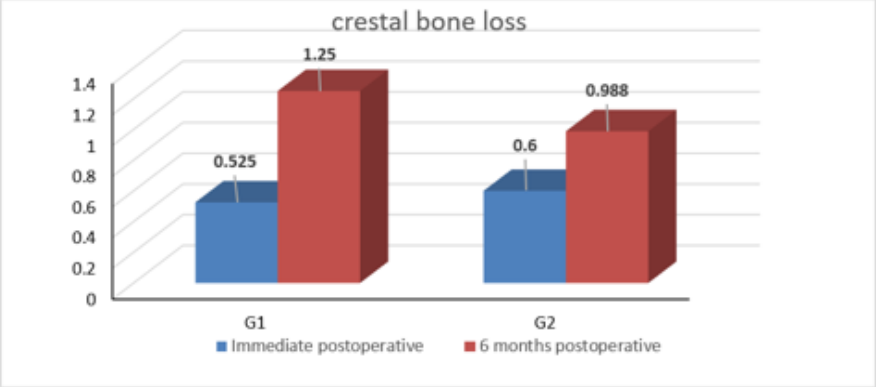

Figure 11: Graph Showing the Crestal Bone Loss for both Groups Immediately and 6 Months Postoperatively

A-Intergroup Comparisons:

At Immediate

G1 (Mean = 0.525±0.149) and G2 (Mean = 0.600±0.107) show no significant difference (P = 0.266), indicating similar initial crestal bone height between the groups.

6 Months Results:

G1 (Mean = 1.250±0.193) shows significantly greater bone loss compared to G2 (Mean = 0.988±0.136) with a P value of 0.007.

B-Intragroup Comparisons:

For G1 and G2 there was a significant crestal bone loss measured at 6 months (p<0.001).

3- Bone Density

Mean and Standard deviation (SD) value for crestal bone density in G1 and G2 were presented in Table (4) and figure (12).

Tianjin Daxue Xuebao (Ziran Kexue yu Gongcheng Jishu Ban)/
Journal of Tianjin University Science and Technology
ISSN (Online):0493-2137
E-Publication: Online Open Access
Vol: 59 Issue: 11:2026
DOI: 10.5281/zenodo.24104259

Table 4: Mean and Standard Deviation (SD) Value for Bone Density in Both Groups

	G1		G2		Independent T test	P value
	Mean	SD	Mean	SD		
Immediate	996.25	101.69	981.25	96.43	0.303	0.767
6 Months	1393.75	206.12	1508.75	133.25	1.325	0.206
% change	39.9		53.8			
Paired T test	5.882		16.25			
P value	0.001**		<0.001**			
****,** means significant difference at P<0.01						

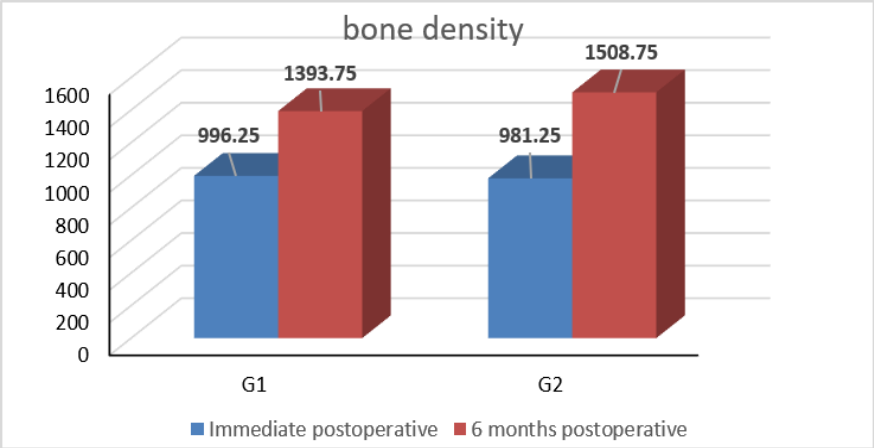

Figure 12: Graph Showing the Bone Density for both Groups Immediately and 6 Months Postoperatively

A-Intergroup Comparisons:

At Immediate

G1 (Mean = 996.25±101.69) and G2 (Mean = 981.25±96.43) show no significant difference (P = 0.767), indicating similar initial bone density between the groups.

6 Months Results:

G1 (Mean = 1393.75±206.12) shows no significant difference compared to G2 (Mean = 1508.75±133.25) with a P value of 0.206.

B-Intragroup Comparisons:

For G1 and G2 there was a significant increase in mean value of bone density measured at 6 months (p<0.001 and P<0.001). G1 shows a percentage change of 39.9%, while G2 shows a higher change of 53.8%, indicating that G2 had a greater relative increase over time.

4- Implant Stability

Mean and Standard deviation (SD) value for implant stability in G1 and G2 were presented in Table (5) and figure (13)

Tianjin Daxue Xuebao (Ziran Kexue yu Gongcheng Jishu Ban)/
Journal of Tianjin University Science and Technology
ISSN (Online):0493-2137
E-Publication: Online Open Access
Vol: 59 Issue: 11:2026
DOI: 10.5281/zenodo.24104259

Table 5: M and standard deviation (SD) value for stability in both groups

	G1		G2		Independent T test	P value
	Mean	SD	Mean	SD		
Immediate	44.50	3.07	46.00	2.73	1.033	0.319
6 Months	82.00	4.90	84.75	4.98	1.114	0.284
% change	84.3		84.2			
Paired T test	21.03		32.939			
P value	<0.001**		<0.001**			
****,** means significant difference at P<0.01						

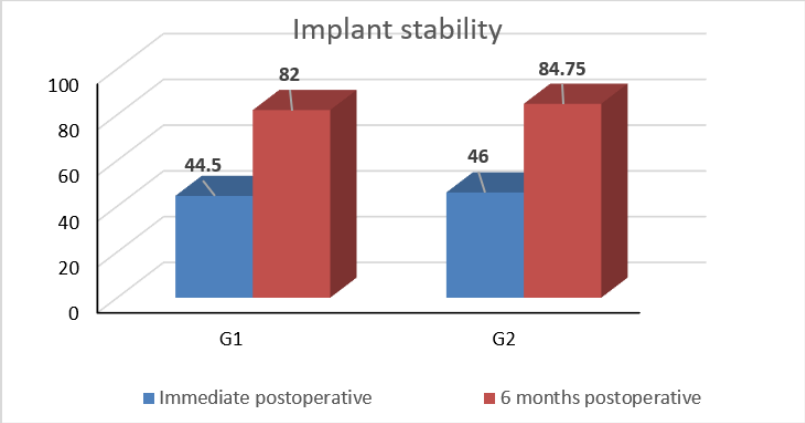

Figure 13: Graph Showing Implant Stability for both Groups Immediately and 6 Months Postoperatively

A-Intergroup Comparisons:

At Immediate Results:

G1 (Mean = 44.50±3.07) and G2 (Mean = 46.00±2.73) show no significant difference (P = 0.319), indicating similar initial values.

6 Months Results:

G1 (Mean = 82.00±4.90) and G2 (Mean = 84.75±4.98) also show no significant difference (P = 0.284), suggesting comparable outcomes at the 6-month follow-up.

B-Intragroup Comparisons:

For G1 and G2 there was a significant increase in mean value of implant stability measured at 6 months (p<0.001 and P<0.001). Both groups show similar percentage changes (G1: 84.3%, G2: 84.2%).

DISCUSSION

The present randomized clinical study evaluated the effect of grafting the peri-implant jumping gap with sticky bone around immediate implants placed into fresh extraction sockets of single-rooted maxillary teeth. After six months, grafting produced a statistically

Tianjin Daxue Xuebao (Ziran Kexue yu Gongcheng Jishu Ban)/
Journal of Tianjin University Science and Technology
ISSN (Online):0493-2137
E-Publication: Online Open Access
Vol: 59 Issue: 11:2026
DOI: 10.5281/zenodo.24104259

significant preservation and gain in buccal bone width compared with non-grafted sites, while no significant differences were observed between groups in bone density or implant stability. The grafted group also demonstrated a trend toward less crestal bone loss.

Clinical Outcomes and Complications:

Short-term implant survival in this cohort was 100% regardless of grafting, indicating that immediate implant placement when performed with careful atraumatic extraction, appropriate implant selection, and primary stability can achieve excellent early survival rates. This aligns with several reports showing high short-term survival after immediate placement (Juodzbalys et al., 2007) and supports the clinical viability of immediate placement even without simultaneous grafting in selected cases. However, the higher level evidence summarized by Lang et al., 2012, reporting an annual failure rate of 0.82% (2-year survival ~98.4%), suggests that larger samples and longer follow-up typically reveal small absolute failure rates; our small sample size and limited follow-up likely account for the difference. Two of 16 implants developed peri-implantitis in the early postoperative period but resolved with conservative management (chlorhexidine rinse) and exhibited healthy peri-implant soft tissue by study end. The low complication rate is comparable to Chen et al., 2007, who reported peri-implantitis in 2 of 62 immediately placed implants, with one implant failure, whereas other studies (Juodzbalys et al., 2007) have reported uneventful healing. These findings highlight that with rigorous surgical technique and postoperative care, early inflammatory complications can be managed successfully.

Buccal Bone Width:

The most pronounced and clinically relevant effect observed was the significant increase in buccal bone width in grafted sites (approximately 33.7% gain) versus marked reduction in the non-grafted group (≈25.9% loss) at six months. This result supports the concept that filling the horizontal peri-implant gap with an osteoconductive, moldable material can mitigate resorption of the thin buccal plate and, in our study, promote net bone gain. Our findings concur with prior clinical and experimental data showing that thin buccal plates are prone to resorption after extraction and immediate implant placement if not augmented (Botticelli et al., 2004). The observed buccal bone preservation in grafted sites is also consistent with reports that xenografts can limit horizontal ridge resorption when compared with no graft.

Bone Density and Defect Healing:

Despite the clear effect on buccal width, mean bone density did not differ significantly between groups at six months; both groups showed a significant increase in density from baseline. This suggests that within the 6-month healing window intrinsic bone healing around immediate implants can progress sufficiently to increase radiographic density irrespective of grafting for gaps of the sizes treated here. Animal studies have demonstrated that self-contained peri-implant defects up to ~2.25 mm can spontaneously fill with new bone within a few months without grafting (Botticelli et al., 2004), which concords with our density findings. Moreover, experimental work comparing Bio-Oss®

Tianjin Daxue Xuebao (Ziran Kexue yu Gongcheng Jishu Ban)/
Journal of Tianjin University Science and Technology
ISSN (Online):0493-2137
E-Publication: Online Open Access
Vol: 59 Issue: 11:2026
DOI: 10.5281/zenodo.24104259

grafted versus non-grafted defects has produced mixed results: some studies report incorporation of graft particles into newly formed bone (Botticelli et al., 2004), whereas others found no added advantage of Bio-Oss® for defect closure in certain defect geometries (Botticelli et al., 2004; Polyzois et al., 2007). Thus, radiographic bone density alone may not capture qualitative differences in bone remodeling or the spatial distribution of new bone versus residual graft.

Crestal Bone Changes:

Both groups experienced significant crestal bone loss at six months, with non-significantly higher mean loss in the control group. The lack of a statistically significant difference between groups may reflect the modest sample size and heterogeneity in crestal remodeling among individual sites and patients. Literature on crestal remodeling after immediate implantation is heterogeneous; some studies report limited differences between grafted and non-grafted approaches (Sanivarapu et al., 2010), while others recommend augmentation in esthetic zones to optimize marginal contours (Becker *et al.,* 2006). Differences in surgical technique, implant design, soft tissue phenotype, and measurement methods likely contribute to interstudy variability. Our results nonetheless suggest that while grafting significantly affects horizontal buccal thickness, its effect on marginal vertical bone loss may be smaller or require longer observation to become evident.

Implant Stability:

Implant stability increased significantly in both groups from insertion to six months, with no difference between grafted and non-grafted sites. This pattern mirrors previous clinical reports showing progressive increases in ISQ values over time for immediate implants (Somraj et al., 2020) and studies reporting no stability advantage with simultaneous grafting versus delayed approaches (Chu et al., 2012). Animal work comparing autogenous bone to HA/β-TCP grafts similarly revealed no short-term differences in stability. Collectively, these data imply that primary mechanical stability and subsequent biological osseointegration are primarily influenced by implant design and surgical technique, whereas grafting the horizontal gap may not significantly alter ISQ-measured stability over the short term.

Sticky Bone as Graft Material:

Sticky bone (S1), a bovine HA xenograft combined into a cohesive fibrin-rich matrix, was used in this study. Recent systematic reviews and clinical studies report favorable clinical and radiographic outcomes with sticky bone across various periodontal and ridge augmentation procedures, noting its handling advantages, graft stability, and promotion of bone fill (Sareen et al., 2024b). The beneficial effect on buccal width observed here likely reflects both the osteoconductive properties of the HA scaffold and the physical stability provided by the fibrin network that maintains graft position within the horizontal gap during early healing.

Tianjin Daxue Xuebao (Ziran Kexue yu Gongcheng Jishu Ban)/
Journal of Tianjin University Science and Technology
ISSN (Online):0493-2137
E-Publication: Online Open Access
Vol: 59 Issue: 11:2026
DOI: 10.5281/zenodo.24104259

Limitations and Future Directions:

The principal limitations of this study are the small sample size, short six-month follow-up, and reliance on radiographic measures rather than histologic evaluation. These factors limit the generalizability of the findings and preclude definitive conclusions about long-term marginal bone stability and true bone formation versus residual graft presence. Future larger randomized trials with extended follow-up and, where possible, histologic or micro-CT evaluation would clarify the longevity of buccal bone preservation and the biological fate of sticky bone grafts. Additionally, stratifying by buccal bone thickness, soft tissue biotype, and gap width could identify clinical scenarios where grafting offers the greatest benefit.

CONCLUSIONS

Within the limitations of this randomized clinical study, grafting the peri-implant horizontal gap with sticky bone during immediate implant placement resulted in significantly greater buccal bone width and a trend toward reduced crestal bone loss, while bone density and implant stability at six months did not differ from non-grafted sites. These results suggest that sticky bone can effectively preserve horizontal buccal contours in immediate implant situations, but larger and longer studies are required to confirm these short-term benefits and determine their impact on long-term aesthetic and functional outcomes.

Reference

1) Araújo, M. G., Silva, C. O., Souza, A. B., & Sukekava, F. (2019). Socket healing with and without immediate implant placement. In Periodontology 2000 (Vol. 79, Issue 1, pp. 168–177). Blackwell Munksgaard. https://doi.org/10.1111/prd.12252

2) Araújo, M. G., Silva, C. O., Souza, A. B., & Sukekava, F. (2019). Socket healing with and without immediate implant placement. In Periodontology 2000 (Vol. 79, Issue 1, pp. 168–177). Blackwell Munksgaard. https://doi.org/10.1111/prd.12252

3) Atwood D, Coy W. Clinical, cephalometric, and densitometric study of reduction of residual ridges. J Prosth Dent, 1971; 26:280.

4) Babu, R. S. A., & Ogle, O. (2015). Tissue Response: Biomaterials, Dental Implants, and Compromised Osseous tissue. In Dental Clinics of North America (Vol. 59, Issue 2, pp. 305–315). W.B. Saunders. https://doi.org/10.1016/j.cden.2014.10.010

5) Becker W. Immediate implant placement: treatment planning and surgical steps for successful outcomes. Br Dent J. 2006 Aug 26;201(4):199-205. doi: 10.1038/sj.bdj.4813881.

6) Bhola, M., Neely, A. L., & Kolhatkar, S. (2008). Immediate implant placement: Clinical decisions, advantages, and disadvantages. Journal of Prosthodontics, 17(7), 576–581. https://doi.org/10.1111/j.1532-849X.2008.00359.x
Mavrogenis, A. F., Dimitriou, R., Parvizi, J., & Babis, G. C. (2009). Biology of implant osseointegration. Journal of Musculoskeletal & Neuronal Interactions, 9(2), 61–71.

7) Botticelli, D., Berglundh, T., & Lindhe, J. (2004). The influence of a biomaterial on the closure of a marginal hard tissue defect adjacent to implants. An experimental study in the dog. Clinical Oral Implants Research, 15(3), 285–292. https://doi.org/10.1046/j.1600-0501.2003.01008.x

Tianjin Daxue Xuebao (Ziran Kexue yu Gongcheng Jishu Ban)/
Journal of Tianjin University Science and Technology
ISSN (Online):0493-2137
E-Publication: Online Open Access
Vol: 59 Issue: 11:2026
DOI: 10.5281/zenodo.24104259

8) Chu SJ, Salama MA, Salama H, Garber DA, Saito H, Sarnachiaro GO, Tarnow DP. The dual-zone therapeutic concept of managing immediate implant placement and provisional restoration in anterior extraction sockets. Compend Contin Educ Dent. 2012 Jul-Aug;33(7):524-32, 534.

9) Climent, M., Santos-García, R., Jaramillo-Santos, R., Romero-Ruiz, M. M., Fernández-Palacin, A., Lázaro-Calvo, P., Bullón, P., & Ríos-Santos, J. V. (2013). Assessment of Osstell ISQ's reliability for implant stability measurement: A cross-sectional clinical study. Medicina Oral, Patologia Oral y Cirugia Bucal, 18(6). https://doi.org/10.4317/medoral.19120.

10) Groenendijk, E., Staas, T. A., Graauwmans, F. E. J., Bronkhorst, E., Verhamme, L., Maal, T., & Meijer, G. J. (2017). Immediate implant placement: the fate of the buccal crest. A retrospective cone beam computed tomography study. International Journal of Oral and Maxillofacial Surgery, 46(12), 1600–1606. https://doi.org/10.1016/j.ijom.2017.06.026

11) Henry, P. J., & Liddelow, G. J. (2008). Immediate loading of dental implants. In Australian Dental Journal (Vol. 53, Issue SUPPL. 1). https://doi.org/10.1111/j.1834-7819.2008.00044.x

12) Juodzbalys, G., & Wang, H. L. (2007). Soft and hard tissue assessment of immediate implant placement: A case series. Clinical Oral Implants Research, 18(2), 237–243. https://doi.org/10.1111/j.1600-0501.2006.01312.x

13) Kabi, S., Kar, R., Samal, D., Deepak, K. C., Kar, I. B., & Mishra, N. (2020). Immediate dental implant placement with or without autogenous bone graft: A comparative study. National Journal of Maxillofacial Surgery, 11(1), 46–52. https://doi.org/10.4103/njms.NJMS_59_19

14) Kastala, V. (2018). Methods to measure implant stability. Journal of Dental Implants, 8(1), 3. https://doi.org/10.4103/jdi.jdi_7_18

15) Lang NP, Lui P, Lau KY, Li KY, Wong MCM. A systematic review on survival and success rates of implants placed immediately into fresh extraction sockets after at least 1 year. Clin. Oral Impl. Res. 23(Suppl. 5), 2012, 39–66

16) Liñares, A., Dopico, J., Magrin, G., & Blanco, J. (2023). Critical review on bone grafting during immediate implant placement. In Periodontology 2000 (Vol. 93, Issue 1, pp. 309–326). John Wiley and Sons Inc. https://doi.org/10.1111/prd.12516

17) Mavrogenis, A. F., Dimitriou, R., Parvizi, J., & Babis, G. C. (2009). Biology of implant osseointegration. Journal of Musculoskeletal & Neuronal Interactions, 9(2), 61–71.

18) Meredith N. Assessment of implant stability as a prognostic determinant. Int J Prosthodont. 1998;11:491–501.

19) Misch C. Dental implant prosthetics, Mosby, St Louis, 2005.

20) Mohammed, E. E. (2020). immediate implant placement combined with sticky bone and enriched fibrin membrane for teeth exhibiting periapical pathosis. 3, 105–112.

21) Naiem, S. N., Al-Nawas, B., Tawfik, O. K., & El-Nahass, H. (2024). Jumping gap in immediate implant placement in the esthetic zone: A virtual implant planning using cone-beam computed tomography. Journal of Prosthodontic Research, 68(2), 347–353. https://doi.org/10.2186/jpr.JPR_D_23_00033

22) Naitoh, M., Nabeshima, H., Hayashi, H., Nakayama, T., Kurita, K., & Ariji, E. (2010). Postoperative assessment of incisor dental implants using cone-beam computed tomography. The Journal of Oral Implantology, 36(5), 377–384. https://doi.org/10.1563/AAID-JOI-D-09-00080

23) Polyzois, I., Renvert, S., Bosshardt, D. D., Lang, N. P., & Claffey, N. (2007). Effect of Bio-Oss on osseointegration of dental implants surrounded by circumferential bone defects of different dimensions: an experimental study in the dog. Clinical Oral Implants Research, 18(3), 304–310. https://doi.org/10.1111/j.1600-0501.2007.01207.x

Tianjin Daxue Xuebao (Ziran Kexue yu Gongcheng Jishu Ban)/
Journal of Tianjin University Science and Technology
ISSN (Online):0493-2137
E-Publication: Online Open Access
Vol: 59 Issue: 11:2026
DOI: 10.5281/zenodo.24104259

24) Ryu, H. S., Namgung, C., Lee, J. H., & Lim, Y. J. (2014). The influence of thread geometry on implant osseointegration under immediate loading: A literature review. In Journal of Advanced Prosthodontics (Vol. 6, Issue 6, pp. 547–554). Korean Academy of Prosthodontic. https://doi.org/10.4047/jap.2014.6.6.547

25) Sales, A., Singh, A., Zehra, M., & Naim, H. (2023). Journal of International Dental and Medical Research ISSN 1309-100X Factors Affecting Osseointegration of Dental Implants Ann Sales et al Volume • 16 • Number • 3 • 2023 Review. In J Int Dent Med Res (Vol. 16, Issue 3). http://www.jidmr.com

26) Sanivarapu, S., Dwarakanath, C., & Ramesh, A. (2010). Immediate Implant Placement Following Tooth Extraction: A Clinical and Radiological Evaluation. International Journal of Oral Implantology & Clinical Research, 67–76. https://doi.org/10.5005/jp-journals-10012-1011

27) Sareen, V., K, S., Saxena, I., Selvaraj, U., P, V., Chauhan, S., & M, G. (2024a). Role of Sticky Bone in the Management of Various Alveolar Bone Defects: A Systematic Review. Cureus. https://doi.org/10.7759/cureus.63561

28) Sareen, V., K, S., Saxena, I., Selvaraj, U., P, V., Chauhan, S., & M, G. (2024b). Role of Sticky Bone in the Management of Various Alveolar Bone Defects: A Systematic Review. Cureus. https://doi.org/10.7759/cureus.63561

29) Schultz AJ. Guided tissue regeneration of non submerged implants in immediate extraction sites, Practical Periodontics and Aesthetic Dentistry, 1993; 5:59.

30) Tan WL, Wong TL, Wong MC, Lang NP. A systematic review of post-extractional alveolar hard and soft tissue dimensional changes in humans. Clin Oral Implants Res. 2012 Feb;23 Suppl 5:1-21. doi: 10.1111/j.1600-0501.2011.02375.x. PMID: 22211303.

31) Udeabor, S. E., Heselich, A., Al-Maawi, S., Alqahtani, A. F., Sader, R., & Ghanaati, S. (2023). Current Knowledge on the Healing of the Extraction Socket: A Narrative Review. In Bioengineering (Vol. 10, Issue 10). Multidisciplinary Digital Publishing Institute (MDPI). https://doi.org/10.3390/bioengineering10101145

32) Van der Weijden F, Dell'Acqua F, Slot DE. Alveolar bone dimensional changes of post-extraction sockets in humans: a systematic review. J Clin Periodontol. 2009 Dec;36(12):1048-58. doi: 10.1111/j.1600-051X.2009.01482.x.

33) Wu, D., Zhou, L., Lin, J., Chen, J., Huang, W., & Chen, Y. (2019). Immediate implant placement in anterior teeth with grafting material of autogenous tooth bone vs xenogenic bone. BMC Oral Health, 19(1). https://doi.org/10.1186/s12903-019-0970-7.

34) Yiğit Özer S. Detection of Vertical Root Fractures by Using Cone Beam Computed Tomography with Variable Voxel Sizes in an In Vitro Model. J. Endod. 2011;37:75–79. doi: 10.1016/j.joen.2010.04.021.