Tianjin Daxue Xuebao (Ziran Kexue yu Gongcheng Jishu Ban)/
Journal of Tianjin University Science and Technology
ISSN (Online):0493-2137
E-Publication: Online Open Access
Vol: 59 Issue: 11:2026
DOI: 10.5281/zenodo.24412051

CLINICAL EVALUATION OF MANDIBULAR POSTERIOR SCREW-RETAINED ZIRCONIA CROWN WITH VARIOUS TI-BASE ABUTMENT SURFACE TREATMENT RANDOMIZED CONTROLLED CLINICAL TRIAL

MOHAMED TAREK ABEL TAWAB SALAM*
MSc Candidate, Department of Prosthodontics, Faculty of Dentistry, October University for Modern Sciences and Arts (MSA), Egypt. *Corresponding Author Email: mohamed.tarek62@msa.edu.eg
ORCID: https://orcid.org/0009-0001-1179-5684

Dr. HESHAM AMR ABOUDORRA
Lecturer of Prosthodontics, Faculty of Dentistry, October University for Modern Sciences and Arts (MSA), Egypt. Email: hamr@msa.edu.eg, ORCID: https://orcid.org/0009-0000-2423-2998

Dr. DINA MOHAMED ELAWADY
Professor of Prosthodontics, Faculty of Dentistry, October University for Modern Sciences and Arts (MSA), Egypt. Email: delawady@msa.edu.eg, ORCID: https://orcid.org/0000-0002-8407-4749

Abstract

Purpose: To evaluate the clinical effects of different Ti-base surface treatments on mandibular posterior screw-retained zirconia crowns. **Materials and Methods:** Twenty-seven partially edentulous patients with a missing mandibular first molar were randomly allocated to three groups: untreated Ti-bases (Group I), tribochemical silica coating (Group II), and tribochemical silica coating combined with a 10-methacryloyloxydecyl dihydrogen phosphate (10-MDP) primer (Group III). Zirconia crowns were extraorally cemented to the Ti-bases. Survival rate outcomes were evaluated according to modified USPHS criteria over a 12-month follow-up period, including decementation and marginal adaptation. Peri-implant biological parameters were assessed using the modified Plaque Index (mPI) and modified Sulcus Bleeding Index (mSBI). **Results:** At the 12-month follow-up, statistically significant differences were observed among the three groups in decementation, mPI, and mSBI ($P < 0.05$), whereas marginal adaptation showed no statistically significant intergroup difference ($P = 0.211$). Group I demonstrated the highest decementation rate (77.8%), followed by Group II (33.3%) and Group III (11.1%). Group III also showed the most favorable peri-implant biological outcomes, with the lowest mPI and mSBI scores (0.22 ± 0.44 for both indices), followed by Group II. Group I demonstrated the least favorable clinical and biological outcomes. **Conclusion:** Combining tribochemical silica coating with an MDP primer was associated with lower decementation rates and more favorable peri-implant biological outcomes over 12 months.

Keywords: Dental Implants; Zirconia; Titanium; Surface Properties; Randomized Controlled Trial.

INTRODUCTION

The long-term success of implant-supported restorations depends not only on implant osseointegration but also on the stability and durability of the prosthetic components and their interfaces. Screw-retained monolithic zirconia restorations have become an established option for posterior implant rehabilitation because of their favorable mechanical properties and clinical performance. However, the titanium base-zirconia (Ti-base) interface remains susceptible to technical complications, particularly debonding which may compromise the survival of the restoration. Because the characteristics of the titanium bonding surface can influence the bonding stability of zirconia–Ti-base

Tianjin Daxue Xuebao (Ziran Kexue yu Gongcheng Jishu Ban)/
Journal of Tianjin University Science and Technology
ISSN (Online):0493-2137
E-Publication: Online Open Access
Vol: 59 Issue: 11:2026
DOI: 10.5281/zenodo.24412051

restorations, investigation of appropriate Ti-base surface-conditioning protocols is clinically relevant.[1–3]

Various surface-conditioning strategies have been investigated to improve bonding between zirconia restorations and Ti-base abutments. Airborne-particle abrasion modifies the titanium surface by increasing it's surface roughness and has been reported to improve the bonding of restorations to Ti-base abutments. Tribochemical silica coating, using silica-modified alumina particles such as the CoJet system, provides a silica-modified surface that may facilitate subsequent chemical interaction with resin materials.[4,5] Chemical primers containing functional phosphate monomers, such as 10-methacryloyloxydecyl dihydrogen phosphate (10-MDP), have also been investigated to promote chemical interaction at the titanium–resin interface. Recent in vitro evidence demonstrated that application of a 10-MDP-containing primer increased the pull-out force of zirconia crowns bonded to Ti-base abutments. However, the magnitude of the benefit obtained from combining mechanical surface conditioning with chemical priming may depend on the specific surface-treatment protocol, bonding material, and restoration configuration.[6]

Although these laboratory findings provide evidence supporting the investigation of Ti-base surface conditioning, their clinical relevance cannot be assumed because bonding stability may be influenced by functional loading, moisture, temperature fluctuations, and the complex oral environment. Furthermore, laboratory studies evaluating bond strength or pull-out force do not necessarily reflect the clinical behavior of restorations during prolonged intraoral function. Clinical evaluation is therefore necessary to determine whether differences observed among surface-conditioning protocols translate into meaningful differences in prosthetic performance. [7]

Despite the growing laboratory evidence regarding Ti-base surface conditioning, clinical evidence directly comparing different conditioning protocols remains limited. In particular, the relative clinical performance of untreated titanium surfaces, Tribochemical silica-coated surfaces, and surfaces receiving both mechanical conditioning and subsequent chemical priming has not been sufficiently established. This clinical uncertainty provides a rationale for evaluating these approaches under intraoral functional conditions rather than assuming that improvements demonstrated in laboratory testing will necessarily result in superior clinical outcomes.

Accordingly, the present randomized controlled clinical trial evaluated three Ti-base surface-conditioning protocols: untreated Ti-base surfaces, Tribochemical silica coating alone, and Tribochemical silica coating followed by application of 10-MDP primer. The primary prosthetic outcomes were decementation and marginal adaptation, assessed using selected modified United States Public Health Service (USPHS) criteria, which has reported in recent clinical research for evaluating clinical performance of posterior Screw-retained Zirconia Crowns.[8]

Marginal adaptation represents an important prosthetic parameter and is influenced by multiple factors, including restoration design, cement space, manufacturing accuracy,

Tianjin Daxue Xuebao (Ziran Kexue yu Gongcheng Jishu Ban)/
Journal of Tianjin University Science and Technology
ISSN (Online):0493-2137
E-Publication: Online Open Access
Vol: 59 Issue: 11:2026
DOI: 10.5281/zenodo.24412051

and cementation variables. Recent in vitro studies have demonstrated clinically acceptable marginal and internal fit for different Ti-base–zirconia crowns while also indicating that cement-gap dimensions, cement type and cementation protocol may influence fit and bonding.[9,10]

The modified plaque index (mPI) and modified sulcus bleeding index (mSBI) were included as secondary biological outcomes to monitor plaque accumulation and peri-implant mucosal inflammatory status during follow-up. Peri-implant plaque accumulation and mucosal inflammation are important clinical indicators of peri-implant tissue health. [11] However, these parameters do not directly measure the integrity of the zirconia–Ti-base bonded interface. Therefore, mPI and mSBI were considered complementary clinical parameters for monitoring peri-implant tissue conditions during the follow-up period rather than direct measures of the effect of the internal Ti-base surface treatment.

Based on the available laboratory evidence and the limited clinical evidence comparing these surface-conditioning approaches, this randomized controlled clinical trial was designed to determine whether differences in Ti-base surface treatment would influence the survival rate of mandibular posterior Screw-retained Zirconia Crown. The study specifically compared untreated Ti-base surfaces, Tribochemical silica coating alone, and Tribochemical silica coating followed by application of a 10-MDP primer. The primary outcomes were survival rate: decementation and marginal adaptation, while mPI and mSBI were assessed as secondary peri-implant biological outcomes. The null hypothesis was that the three Ti-base surface-conditioning protocols would have no statistically significant effect on decementation or marginal adaptation over the 12-month follow-up period.

MATERIALS AND METHODS

- **Methods**

I. Study design

A randomized controlled clinical trial with a prospective, parallel-arm design was carried out to assess the impact of various surface treatment protocols on Ti-Base abutments before cementation. The study aimed to determine how these treatments affect the clinical survival and peri-implant biological health of mandibular posterior screw-retained zirconia crown.

Operator Standardization

To ensure methodological consistency and eliminate inter-operator variability and ensure consistency throughout the study, all clinical and laboratory procedures were performed by the principal researcher. These included digital treatment planning, implant placement surgery, prosthetic procedures, Ti-base surface treatment, extraoral cementation, and all clinical follow-up assessments. All procedures were carried out according to the study protocol.

Tianjin Daxue Xuebao (Ziran Kexue yu Gongcheng Jishu Ban)/
Journal of Tianjin University Science and Technology
ISSN (Online):0493-2137
E-Publication: Online Open Access
Vol: 59 Issue: 11:2026
DOI: 10.5281/zenodo.24412051

Ethical Approval

The study was approved by the Research Ethics Committee of the Faculty of Dentistry, October University for Modern Sciences and Arts, under approval code REC-D 44012-4. The study was conducted in accordance with the principles of the Declaration of Helsinki. Written informed consent was obtained from all participants before enrolment in the study. Participant recruitment and data collection commenced after ethical approval had been granted. The clinical trial was registered at ClinicalTrials.gov under registration number NCT07456995.

Sample Size Calculation

Sample size calculated depending on a previous pilot study. The findings of a previous pilot study, regarding decementation, in group I after 6 months Alpha score was 25%, Delta score was 75%, in Group II Alpha score was 66.6%, Delta score was 33.4%. The minimal accepted sample size is 7 in group with (0.96) effect size when probability (power) was 0.8 and Type I error probability associated with this test was 0.05. We used X2 test by using G*Power 3.1.9.4 software. Total sample size increased to 9 per group to compensate for a 20 % drop out. Total sample size: 9 for each group.

II. Participant Selection

Twenty-seven eligible participants were recruited from the outpatient clinic and randomly allocated into three groups from the outpatient clinic of October University for Modern Sciences and Arts (MSA). Participants entered the study through routine implant consultation appointments, where eligibility was confirmed through history taking, clinical examination, and imaging-based site assessment using periapical and panoramic radiographs.

a. Inclusion Criteria

Participants were selected according to the following criteria:

i. Age between 18 – 55 years old.

ii. Partial edentulous Participants with a missing mandibular first molar, opposing either a fully dentulous arch or a partially edentulous arch with one or two missing teeth, but retaining the first molar and second premolar opposing the missing mandibular first molar.

iii. According to the American Society of Anesthesiologists (ASA) participant were chosen from ASA I (healthy) or ASA II (mild systemic disease).

iv. Good oral hygiene.

v. Angle class I occlusal relationship. (Angle's Classification)

vi. No evident signs of occlusal parafunction and/or temporomandibular disorders.

vii. No pregnancy or lactation.

viii. Non-Smokers and light smokers (≤10 cigarettes/day).

Tianjin Daxue Xuebao (Ziran Kexue yu Gongcheng Jishu Ban)/
Journal of Tianjin University Science and Technology
ISSN (Online):0493-2137
E-Publication: Online Open Access
Vol: 59 Issue: 11:2026
DOI: 10.5281/zenodo.24412051

ix. Absence of infection at the implant site, with sufficient bone volume and quality to receive a dental implant Ø4.5*10.0mm. Bone quality was classified as D1–D2 according to Misch, while bone volume was categorized as Division A according to the Misch–Judy classification system.[12]

x. Adequate prosthetic space to receive an adequate screw - retained zirconia restoration: measuring at least 10mm mesiodistal space between adjacent teeth with a minimum of 7.5mm at the CEJ and 8–10 mm from the residual ridge to the opposing occlusion.

xi. Presence of adequate keratinized tissue (≥2 mm) at the implant site to ensure soft tissue stability and peri-implant gingival health.

b. Exclusion Criteria

Participants were excluded according to the following criteria

i. General and medical contraindication for surgical procedures.

ii. Poor oral hygiene & periodontal disease.

iii. Reduced prosthetic space at the edentulous site.

iv. Severe wear facets, clenching, and bruxism.

v. Heavy smokers (>10 cigarettes/day).

III. Participant Approvals

Prior to enrollment, all participants received comprehensive information regarding the study's nature, aims, and procedures. The protocol was communicated both orally and in written and digitalized forms with animated video of the proposed treatment to guarantee full comprehension, with ample opportunity provided for questions. Appropriate measures were taken to ensure the confidentiality, privacy, and security of all personal data.

Eligible participants were further informed about the potential benefits and risks of the study after confirming inclusion and exclusion criteria. The complete clinical pathway—including surgical procedures, restorative steps, follow-up visits, and possible complications such as surgical risks, restoration decementation, screw loosening, or chipping was clearly explained. Enrollment was finalized only after obtaining written informed consent from all participants.

Randomization and Allocation of Participants

Participants who met the inclusion criteria were randomly allocated into three equal groups using a blocked randomization method to ensure balanced group distribution. The allocation sequence was generated by an independent researcher who was not involved in participant recruitment or treatment procedures to minimize bias. Allocation concealment was achieved using sequentially numbered, opaque, sealed envelopes. The overall study design, including group allocation, treatment protocols, and clinical follow-up, is illustrated in (Fig. 1).

Tianjin Daxue Xuebao (Ziran Kexue yu Gongcheng Jishu Ban)/
Journal of Tianjin University Science and Technology
ISSN (Online):0493-2137
E-Publication: Online Open Access
Vol: 59 Issue: 11:2026
DOI: 10.5281/zenodo.24412051

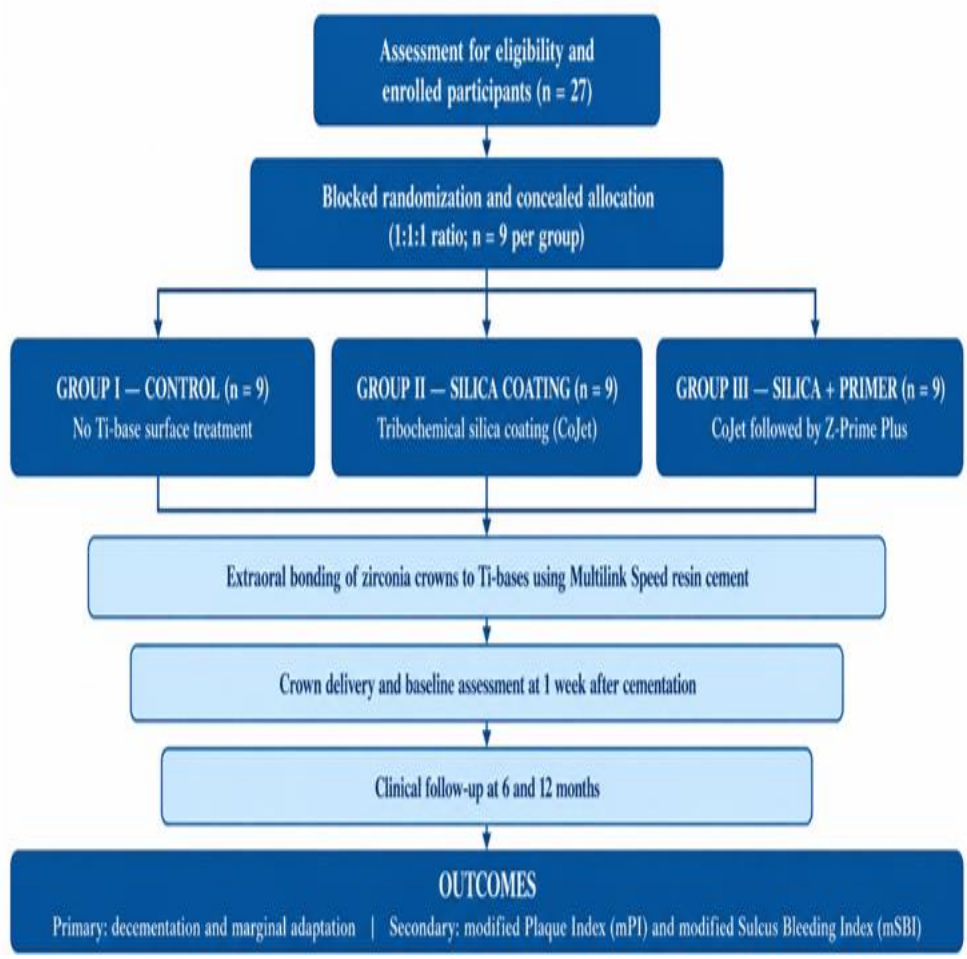

Figure 1: Schematic Diagram of the Study Design

Group I (Control): Nine Participants received screw-retained zirconia crowns cemented to Ti-base abutments without any surface treatment prior to resin cementation.

Group II: Nine Participants received screw-retained zirconia crowns cemented to Ti-base abutments after Tribochemical silica coating using CoJet™ Sand (30-µm silica-coated aluminum oxide particles; 3M ESPE AG, Seefeld, Germany) surface treatment.

Group III: Nine Participants received screw-retained zirconia crowns cemented to Ti-base abutments after Tribochemical silica coating using (CoJet system) surface treatment followed by application of (MDP)-containing primer (Z-Prime™ Plus; BISCO, Inc., Schaumburg, IL, USA) prior to resin cementation.

IV. Participant History

A) Medical History

Participants were asked about their medical history, including past and current health status and medications.

Tianjin Daxue Xuebao (Ziran Kexue yu Gongcheng Jishu Ban)/
Journal of Tianjin University Science and Technology
ISSN (Online):0493-2137
E-Publication: Online Open Access
Vol: 59 Issue: 11:2026
DOI: 10.5281/zenodo.24412051

B) Dental History

Each participant was asked about the cause of tooth loss of the mandibular first molar (caries, periodontal disease, failed endodontic treatment, or root fracture) to assess possible implications on bone quality and quantity at the implant site. Each participant was asked about the date of extraction of the mandibular first molar to ensure adequate healing time and sufficient bone remodeling prior to implant placement. A minimum healing period of 6 months was confirmed before implant placement. Participants were questioned about any previous implant therapy or prosthetic restorations in the same quadrant to evaluate previous complications, failures, or occlusal problems. Each participant was examined about parafunctional habits such as bruxism or clenching, as these may influence occlusal load distribution and long-term implant restoration survival.

Participants were also asked about their previous experience with fixed or removable dental prostheses to assess their functional expectations, esthetic demands, and possible complaints related to retention, comfort, or occlusion.

V. Participant's Examination

A) Extra-Oral Examination

Participants were examined Extra-orally for: Facial asymmetry, participant profile and facial muscle tone.

B) Intra-Oral examination

Intra-oral examination was performed, and intraoral photographs were taken

- Signs of inflammation, ulceration, or infection in the edentulous area and surrounding tissues.
- Amount and width of keratinized mucosa at the proposed implant site.
- Residual ridge shape, height, and contour at the mandibular first molar region.
- Occlusal relationship and inter-arch space adequacy.
- Condition of the opposing dentition.

C) Radiographic Evaluation

An initial preoperative radiographic assessment was performed for all Participants to evaluate the implant site and confirm eligibility according to the study criteria.

Initial screening included panoramic radiograph (New Tom CBCT/panoramic imaging system; New Tom, Cefla s.c., Imola, Italy) to assess the edentulous region and adjacent structures. These images were used to exclude the presence of pathological lesions, impacted teeth, retained roots, or other conditions that could contraindicate implant placement.

Participants who succeeded in the initial radiographic assessment were subjected to a subsequent Cone-Beam Computed Tomography (New Tom CBCT/panoramic imaging system; New Tom, Cefla s.c., Imola, Italy) radiographic examination. Cross-sectional

Tianjin Daxue Xuebao (Ziran Kexue yu Gongcheng Jishu Ban)/
Journal of Tianjin University Science and Technology
ISSN (Online):0493-2137
E-Publication: Online Open Access
Vol: 59 Issue: 11:2026
DOI: 10.5281/zenodo.24412051

CBCT images (Fig. 2) were used to evaluate the available bone quality and volume, assess the surrounding anatomical structures, and enable prosthetically driven implant planning.

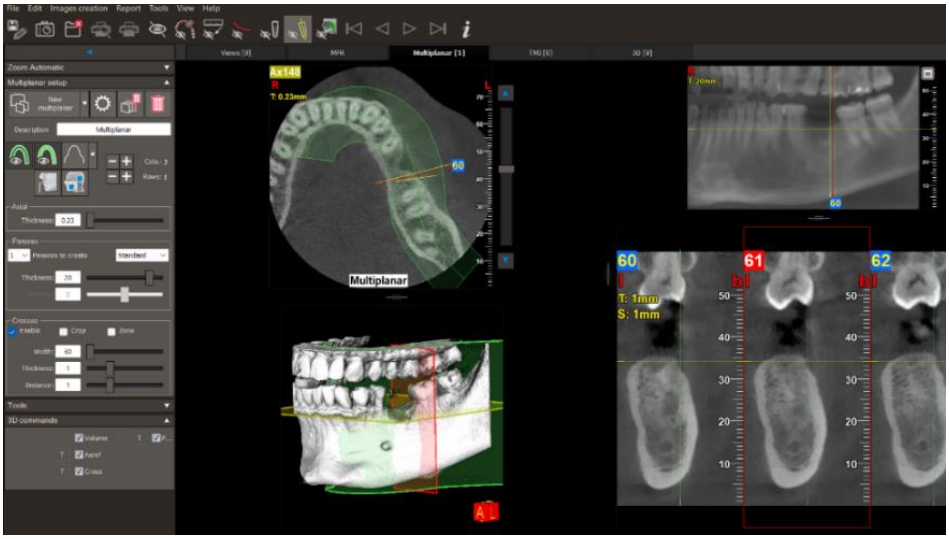

Figure 2: Cross-Sectional CBCT Image

VI. Digital Workflow for Implant Planning and Surgical Guide Fabrication

A) Digital Data Acquisition Scans and Implant Planning

Intraoral digital scans of both maxillary and mandibular arches (Fig.3 a&b) were acquired using the TRIOS 3(TRIOS® 3 Wireless, Shape A/S, Copenhagen, Denmark**.** intraoral scanner) (Fig. 4) Digital implant planning was performed by integrating DICOM data obtained from cone-beam computed tomography (CBCT) with STL files derived from intraoral scans, using the Atomica Implant Planner software (Atomica Technology, Inc., Atlanta, GA, USA). This integration enabled prosthetically driven implant positioning for the replacement of the mandibular first molar (Fig.5 A-D).



Figure 3: A: Intraoral Scan of Upper Arch B: Intraoral Scan of Lower Arch

Tianjin Daxue Xuebao (Ziran Kexue yu Gongcheng Jishu Ban)/
Journal of Tianjin University Science and Technology
ISSN (Online):0493-2137
E-Publication: Online Open Access
Vol: 59 Issue: 11:2026
DOI: 10.5281/zenodo.24412051



Figure 4: 3shape Trios 3 Dental Scanner

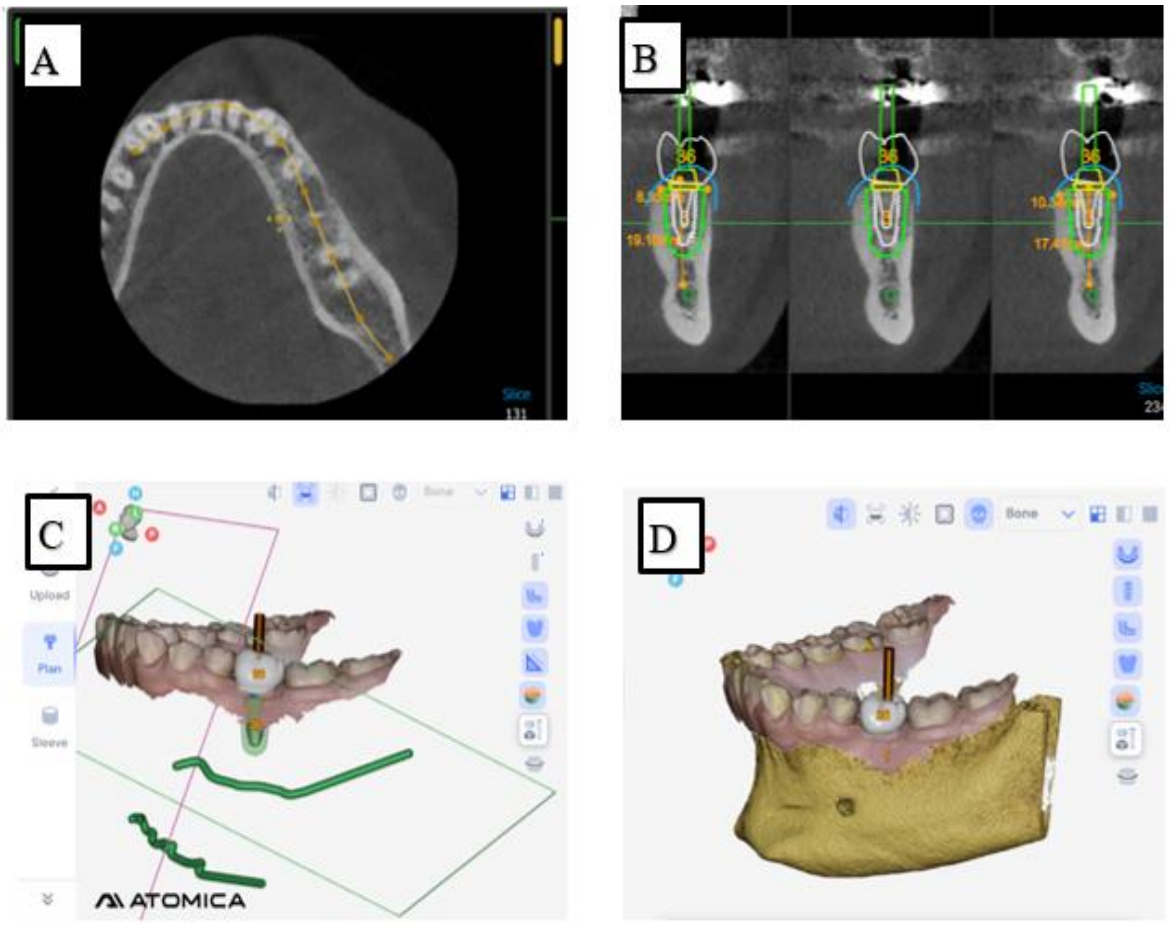

Figure 5: Implant Planning – (A). Axial CBCT View Showing Draw The Mandibular Curve. (B). Cross-Sectional Prosthetically Driven Implant Planning. (C). Three-Dimensional Visualization of the Final Implant Position. (D). Final Implant Position with the Planned First Molar Restoration

Tianjin Daxue Xuebao (Ziran Kexue yu Gongcheng Jishu Ban)/
Journal of Tianjin University Science and Technology
ISSN (Online):0493-2137
E-Publication: Online Open Access
Vol: 59 Issue: 11:2026
DOI: 10.5281/zenodo.24412051

B) Surgical Guide Design, Verification, and Fabrication

A tooth-supported surgical guide was digitally created to rest on the stable adjacent teeth surrounding the missing mandibular first molar site (Fig. 6). It featured a Regular/Wide (R/W) Surgical Guide Sleeve channel designed according to the NeoBiotech guided surgery protocol, with a 10.5 mm offset to enable precise drill angulation and depth control. The guide also incorporated sleeves compatible with the NeoBiotech guided surgery drilling kit (Neo Naviguide Kit, Neo Biotech, South Korea.) (Fig. 7), providing standardized and controlled guidance throughout the implant osteotomy procedure.

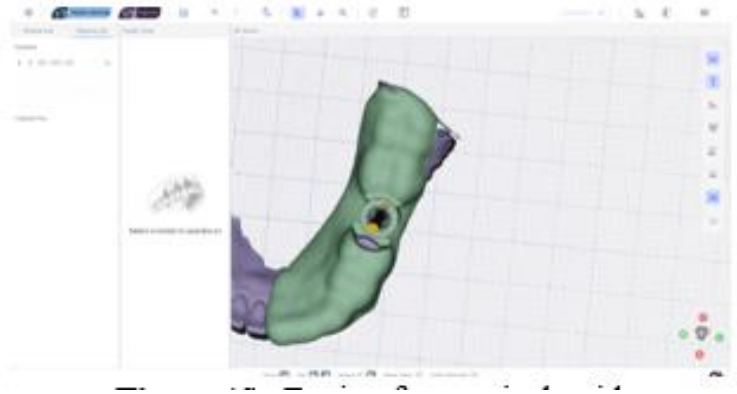

Figure 6: Design for Surgical Guide



Figure 7: Neo Naviguide Kit

Planning was performed using Atomica AI Implant Planner, which integrated CBCT-derived DICOM data with intraoral scan STL files. This workflow enabled accurate implant planning, segmentation and digital guide generation, while also permitting pre-fabrication verification of guide extension, path of insertion, sleeve position, and relation to the supporting teeth.

The finalized design guide was exported as an STL file which was used to 3D print a biocompatible resin (Surgical Guide Resin, IF3165; IFUN3D, Guangzhou, China)surgical guide utilizing a 3D dental printer (Creality HALOT-MAGE PRO 8K, Creality, China) and the additive manufacturing technology. Post-fabrication processing included cleaning, post-curing, and sterilization according to the manufacturer's validated instructions.

Tianjin Daxue Xuebao (Ziran Kexue yu Gongcheng Jishu Ban)/
Journal of Tianjin University Science and Technology
ISSN (Online):0493-2137
E-Publication: Online Open Access
Vol: 59 Issue: 11:2026
DOI: 10.5281/zenodo.24412051

A titanium sleeve was inserted into the printed sleeve channel to provide a rigid, wear-resistant interface between the guide and the drills. This metallic interface standardizes the drilling path, reduces direct contact between the rotating drills and the resin, and enhances mechanical guidance during osteotomy preparation.

Before surgery, the guide was verified intraorally for passive seating, complete fit, and stability on the supporting teeth, and the sleeve position was checked to ensure unobstructed access for the guided drilling sequence.

VII) Surgical Protocol

a) Preoperative Preparation

The Participants were instructed to rinse with 0.12% chlorhexidine mouthwash (Hexitol® mouthwash, chlorhexidine 125 mg/100 mL; Arab Drug Company (ADCO), Cairo, Egypt) three times daily. The surgical armamentarium was sterilized by class B autoclave(Vacuklav® 23 B+, MELAG Medizintechnik GmbH & Co. KG, Germany). On the day of surgery, Participants underwent standard preoperative checks (medical history update, confirmation of ASA status, and verification of the surgical plan).

b) Guided implant placement

Twenty-seven NeoBiotech IS-II Active implants(NeoBiotech IS-II Active Implant, South Korea) were placed in the lower mandibular first molar. These implants feature a tapered design that enhances initial stability and are equipped with progressive threads, which help in optimizing bone engagement. The thread design transitions smoothly from the coronal area, where the threads are wider for better compression, to the apical portion with self-tapping, V-shaped threads to facilitate insertion and secure placement in the bone. The implant is designed with an active apex, providing additional stability for the surrounding bone (Fig. 8).



Figure 8: Neobiotech IS-II Active

At the proposed implant site in the mandibular region, a local anesthetic (Artinibsa® 4% with epinephrine 1:100,000; Laboratorios Inibsa S.A., Barcelona, Spain) was administered both labially and lingually at the insertion point. The already prefabricated

Tianjin Daxue Xuebao (Ziran Kexue yu Gongcheng Jishu Ban)/
Journal of Tianjin University Science and Technology
ISSN (Online):0493-2137
E-Publication: Online Open Access
Vol: 59 Issue: 11:2026
DOI: 10.5281/zenodo.24412051

surgical guide was utilized to ensure precise implant positioning, thereby optimizing placement and stability while preserving the integrity of the soft tissue. The surgical guide was meticulously positioned in the Participant's oral cavity to maintain stability. (Fig. 9).



Figure 9: Surgical Guide with Metal Sleeve Correctly Seated in Place Intra Orally

A surgical implant motor (Implantmed, W&H Dentalwerk, Austria) was used with a 20:1 reduction contra-angle handpiece for final implant insertion, operating at 30 RPM with a torque of 35 Ncm as per the manufacturer's surgical guidelines. The procedure began with a tissue punch (Fig.10 a,b), followed using a 2.0 mm drill. Subsequently, the appropriate osteotomy preparation for the Ø4.5*10.0mm implant was completed using a Ø4.0 mm × 10 mm depth drill (Fig.11). Osteotomy preparation was conducted with the Neo Naviguide Kit through sequential drilling using ample sterile saline irrigation to avoid irreversible bone thermal injury as per the manufacturer's instructions.



Figure 10A: Intraoral Application of the Tissue Punch

Tianjin Daxue Xuebao (Ziran Kexue yu Gongcheng Jishu Ban)/
Journal of Tianjin University Science and Technology
ISSN (Online):0493-2137
E-Publication: Online Open Access
Vol: 59 Issue: 11:2026
DOI: 10.5281/zenodo.24412051



Figure10 B: Ø4.3 Tissue Punch after Soft Tissue Removal



Figure 11: Ø4 Tap Drill

After completion of the osteotomy (Fig. 12), the implant was initially inserted using a surgical implant motor at low speed according to the manufacturer's recommendations. Once primary engagement and correct implant position were achieved, final seating was completed manually using a torque ratchet. The implant gradually advanced until the platform was level with the bone surface, achieving a final insertion torque of 30 Ncm (Fig. 13).



Figure 12: Final Osteotomy

Tianjin Daxue Xuebao (Ziran Kexue yu Gongcheng Jishu Ban)/
Journal of Tianjin University Science and Technology
ISSN (Online):0493-2137
E-Publication: Online Open Access
Vol: 59 Issue: 11:2026
DOI: 10.5281/zenodo.24412051



Figure 13: Implant Placement

Cover screws were subsequently placed (Fig. 14), and a post-surgical radiograph was taken to confirm the final position (Fig. 15).



Figure 14: Cover Screw

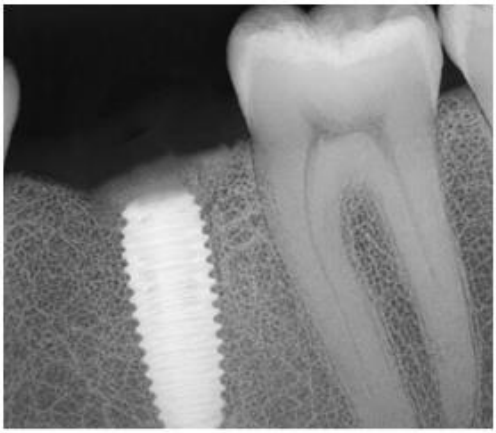

Figure 15: Post Surgical

Tianjin Daxue Xuebao (Ziran Kexue yu Gongcheng Jishu Ban)/
Journal of Tianjin University Science and Technology
ISSN (Online):0493-2137
E-Publication: Online Open Access
Vol: 59 Issue: 11:2026
DOI: 10.5281/zenodo.24412051

c) Postoperative Care and Healing Phase

After implant surgery, all Participants received standardized postoperative instructions, including avoidance of hard food and chewing on the surgical site for 2 weeks and maintaining a good oral hygiene. Prophylactic antibiotic therapy and anti-inflammatory medication were prescribed according to the recommended pharmaceutical guidelines, and all medications, doses, frequencies, durations were recorded in each Participant's medical file.

Participants were instructed to rinse gently with 0.12% chlorhexidine mouthwash twice daily for one minute, starting 24 hours after surgery and continuing for 14 days to support plaque control and soft-tissue healing. A postoperative follow-up visit was scheduled on day 7 after surgery to assess wound healing, detect any signs of infection, and identify early postoperative complications.

VIII. Second-Stage surgery and healing abutment placement

The implant system use in this study was a submerged internal connection implant from NeoBiotech (IS-II Active). A traditional two-stage approach was selected: following implant placement, the implant was left submerged for osseointegration for 3 months. Then a second-stage surgery was conducted to uncover the implant and attach a healing abutment to shape the peri-implant soft tissues. According to the prosthetic documentation provided by the manufacturer for the NeoBiotech IS-II Active implant system, the healing abutment was hand-tightening roughly 10 Ncm. (Fig. 16)



Figure 16: Healing Abutment

A periapical radiograph, employing a standardized long-cone paralleling technique, was utilized to verify the complete seating of the components, observe the peri-implant bone, and establish a radiographic baseline. (Fig. 17)

Tianjin Daxue Xuebao (Ziran Kexue yu Gongcheng Jishu Ban)/
Journal of Tianjin University Science and Technology
ISSN (Online):0493-2137
E-Publication: Online Open Access
Vol: 59 Issue: 11:2026
DOI: 10.5281/zenodo.24412051

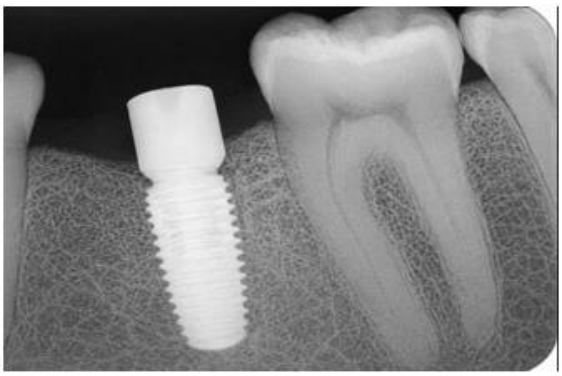

Figure 17: Healing Abutment X-Ray

VIII. Prosthetic workflow and intervention allocation

a) Soft tissue stabilization

After placing the healing abutment, the soft tissues were given time to stabilize before taking the final impression. The protocol allowed for a brief stabilization period of 2 weeks before proceeding with the definitive implant-level impression, aligning with the trial's clinical schedule for completing crown fabrication (Fig. 18).[13]

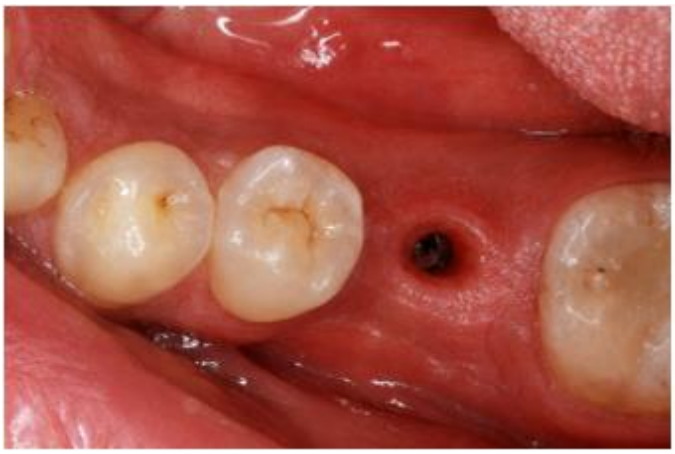

Figure 18: Soft-Tissue Healing

b) Definitive implant impression technique

The definitive implant impression was acquired digitally using the TRIOS 3 intraoral scanner. First, the healing abutment was carefully removed from the implant using a 1.2 mm hex driver. The healing abutment had been previously tightened to the manufacturer's recommended torque of approximately 10 Ncm to ensure stability during the healing period. Once removed, the gingival emergence profile was scanned to capture the contour of the peri-implant soft tissue accurately, providing essential information for the design of the final restoration (Fig. 19).

Tianjin Daxue Xuebao (Ziran Kexue yu Gongcheng Jishu Ban)/
Journal of Tianjin University Science and Technology
ISSN (Online):0493-2137
E-Publication: Online Open Access
Vol: 59 Issue: 11:2026
DOI: 10.5281/zenodo.24412051



Figure 19: Digital Scan of the Gingival Emergence Profile at the Implant Site

Following the soft tissue scan, a NeoBiotech IS System short scan body was light hand-tightening roughly 15 Ncm onto the implant fixture using a 1.2 mm hex driver. The scan body was fully seated and manually verified and then an additional radiographic verification was performed to ensure proper alignment and intimate contact with the implant without applying excessive stress (Fig. 20). The digital scan was then performed, focusing on the implant site, the scan body, the surrounding soft tissue. Digital bite registration was obtained to record the inter-arch relationship (Fig. 21).

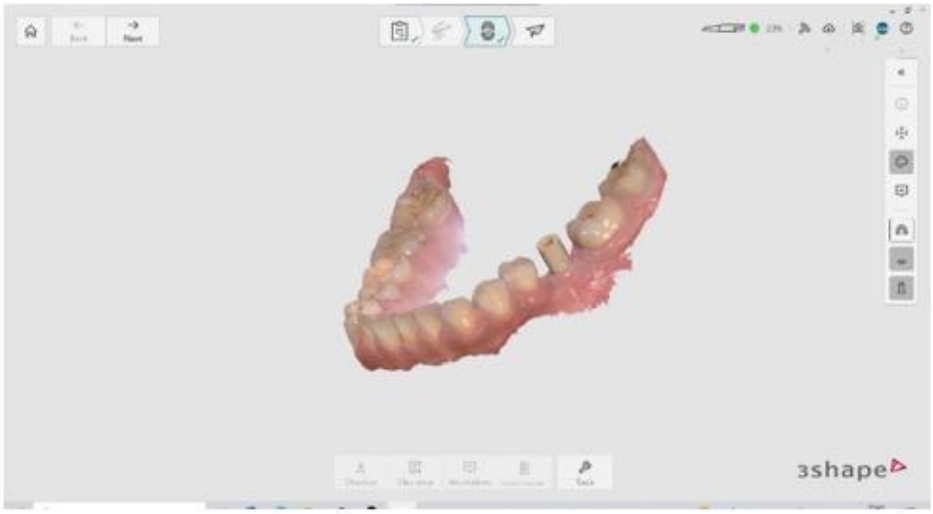

Figure 20: Digital Scan of the Neobiotech Short Scan Body Seated on the Implant

Tianjin Daxue Xuebao (Ziran Kexue yu Gongcheng Jishu Ban)/
Journal of Tianjin University Science and Technology
ISSN (Online):0493-2137
E-Publication: Online Open Access
Vol: 59 Issue: 11:2026
DOI: 10.5281/zenodo.24412051



Figure 21: Digital Bite Scan for Recording the Occlusal Relationship

After scanning, the acquired digital scans were reviewed for any areas of missing data or artifacts were rescanned immediately to guarantee precise replication of the implant position. The final digital impression was exported in STL format and sent to the dental laboratory, where the corresponding laboratory analog was digitally aligned with the scan body. This process ensured accurate reproduction of the intraoral implant position and gingival contours for 3D printing of the master cast and subsequent prosthetic restoration.

c) Digital crown design and clinical try-in

The definitive digital impression was exported in STL format and sent to the dental laboratory. The STL files, including the intraoral scan data, scan body position, and peri-implant soft tissue profile, were imported into Dental CAD software (exocad DentalCAD software; exocad GmbH, Darmstadt, Germany). The software was used in the digital design workflow to determine the implant position and design the proposed screw-retained implant-supported crown. The crown design was adjusted to ensure proper proximal contacts, emergence profile, screw-access channel position, and occlusal anatomy corresponding to a mandibular first molar (Fig. 22).



Tianjin Daxue Xuebao (Ziran Kexue yu Gongcheng Jishu Ban)/
Journal of Tianjin University Science and Technology
ISSN (Online):0493-2137
E-Publication: Online Open Access
Vol: 59 Issue: 11:2026
DOI: 10.5281/zenodo.24412051

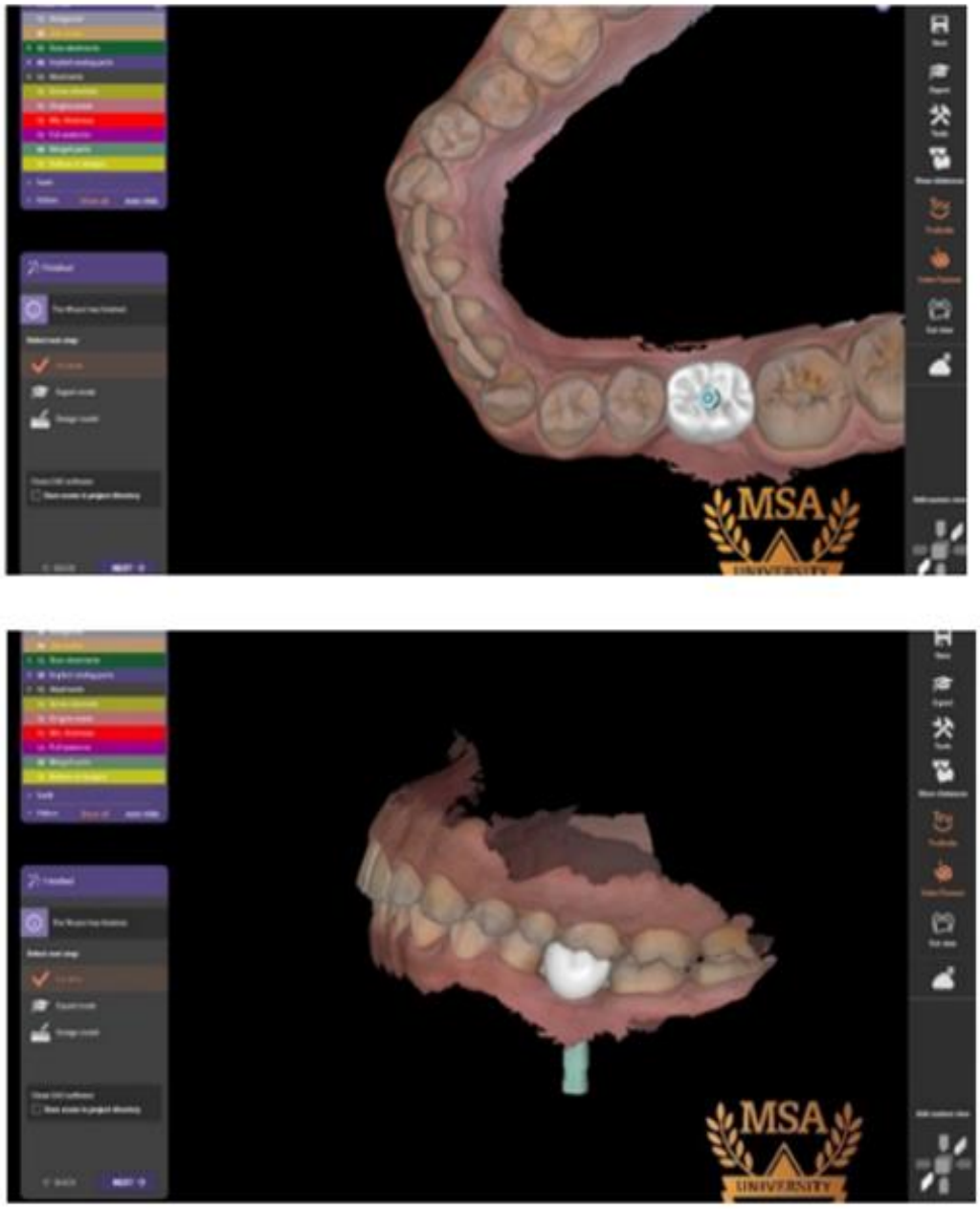

Figure 22: Crown Fabrication

Before fabrication of the definitive zirconia crown, a clinical try-in stage was performed using a 3D-printed provisional resin crown (Norton UV Green Dental Castable 3D-Printing Resin; Norton, China).

The provisional crown was printed using a 3D printer (HALOT-MAGE PRO 8K resin 3D printer; Creality, China) and seated over the Ti-base abutment attached to the implant fixture.

Tianjin Daxue Xuebao (Ziran Kexue yu Gongcheng Jishu Ban)/
Journal of Tianjin University Science and Technology
ISSN (Online):0493-2137
E-Publication: Online Open Access
Vol: 59 Issue: 11:2026
DOI: 10.5281/zenodo.24412051

This step was carried out to verify passive seating, available prosthetic space, occlusal clearance, proximal contacts, emergence profile, and screw-access channel position. In addition, the try-in stage allowed clinical evaluation of the proposed restoration contour and fit before proceeding with fabrication of the definitive zirconia crown.

d) Definitive zirconia crown fabrication

After confirming the clinical acceptability of the try-in 3D printed resin crown, the final approved digital design was used to fabricate the definitive monolithic zirconia crown using CORiTEC 350i PRO+ milling machine (CORiTEC 350i PRO+ milling machine; imes-icore GmbH, Eiterfeld, Germany). The milling procedure reproduced the already planned and tried in implant crown.

e) Zirconia crown surface treatment

All zirconia crowns received a standardized internal surface treatment before extraoral bonding to the Ti-base abutments. The internal bonding surface of each zirconia crown was first air-abraded using 50 µm aluminum oxide particles at 2.0 bar pressure, with the nozzle positioned approximately 10 mm from the surface for 20 seconds.

This step was performed to create micromechanical surface roughness and improve the bonding potential of the zirconia surface. After air abrasion, each crown was immersed in an digital ultrasonic cleaner bath (Digital Ultrasonic Cleaner (3 L, 40 kHz); Shenzhen Codyson Electrical Co., Ltd., Shenzhen, China) containing 96% ethanol for 5 minutes to remove loose alumina particles and surface contaminants produced during airborne-particle abrasion. The crowns were then dried thoroughly using oil-free air.

Z-Prime Plus was then applied to the treated internal bonding surface using a disposable micro brush. Two coats of primer were applied to uniformly wet the entire bonding surface. The primer was allowed to react with the zirconia surface for approximately 30 seconds and was then gently air-dried for 5 seconds until no visible pooling remained.

This zirconia surface-conditioning protocol was applied identically to all crowns in all study groups to standardize the zirconia bonding surface, ensuring that the only experimental variable was the Ti-base surface treatment protocol.

f) Ti-base surface treatment protocols

Participants were allocated into three groups (n=9/group) according to Ti-base surface treatment performed prior to extraoral cementation:

- **Control (Group I):** No surface treatment was performed on the Ti-base bonding surface prior to cementation.
- **Silica coating only (Group II):** The Ti-base bonding surface was treated with Tribochemical airborne-particle abrasion using silica-coated alumina particles using CoJet Sand (Fig. 23).

Tianjin Daxue Xuebao (Ziran Kexue yu Gongcheng Jishu Ban)/
Journal of Tianjin University Science and Technology
ISSN (Online):0493-2137
E-Publication: Online Open Access
Vol: 59 Issue: 11:2026
DOI: 10.5281/zenodo.24412051



Figure 23: Tribochemical Silica-Coating Material

The procedure was performed with a micro blasting device (Alumina Oxide Micro Blaster; Foshan M&Y Medical Instrument Co., Ltd., Foshan, China.) (Fig. 24) to generate micromechanical surface roughness and deposit a silica-rich layer that enhances potential chemical interaction during cementation.



Figure 24: Microblasting Device

The Ti-base bonding surface was treated by Tribochemical silica coating using 30 µm silica-coated alumina particles (CoJet Sand). The blasting protocol was standardized at 2.0 bar pressure, with the nozzle positioned approximately 10 mm from the Ti-base bonding surface for 10 seconds (Fig. 25). Care was taken to restrict surface treatment to the bonding area and avoid the transmucosal collar region.[4]

Tianjin Daxue Xuebao (Ziran Kexue yu Gongcheng Jishu Ban)/
Journal of Tianjin University Science and Technology
ISSN (Online):0493-2137
E-Publication: Online Open Access
Vol: 59 Issue: 11:2026
DOI: 10.5281/zenodo.24412051



Figure 25: Ti-Base Being Treated with Microblasting Device

- **Silica coating + primer (Group III):** The Ti-base bonding surface received the same Tribochemical airborne-particle abrasion protocol as in group II, followed by application of a metal primer Z-Prime Plus (Fig. 26).



Figure 26: Z-Prime Plus

A micro brush was employed to apply a thin, even layer of Z-Prime Plus, and the surface was vigorously scrubbed for 10 seconds to ensure complete wetting between the primer and the treated Ti-base surface. The primer was then left to react for an additional 10 seconds, The primer was then gently dried with an oil-free air syringe for 3–5 seconds, resulting in a properly primed surface as per manufacturer's instructions as shown in (Fig. 27). [14]

Tianjin Daxue Xuebao (Ziran Kexue yu Gongcheng Jishu Ban)/
Journal of Tianjin University Science and Technology
ISSN (Online):0493-2137
E-Publication: Online Open Access
Vol: 59 Issue: 11:2026
DOI: 10.5281/zenodo.24412051



Figure 27: Ti-base surface treatment stages A. Untreated Ti-base. B. Silica coated Ti-base. C. Silica coated Ti- base followed by MDP primer application

g) Cementation

Before resin cement application, the screw-access channel of the Ti-base was temporarily blocked with a small piece of polytetrafluoroethylene (PTFE) tape to prevent resin cement from blocking the screw channel. A self-adhesive resin cement was used for the extraoral luting of the zirconia crown to the Ti-base abutment (Fig. 28). The cement was applied as a carefully controlled thin layer to the bonding interface (Fig. 29), and the crown was initially seated onto the Ti-base along its path of insertion using firm finger pressure.



Figure 28: Multilink® Speed Self-Adhesive Resin Cement



Figure 29: Cement Application

Tianjin Daxue Xuebao (Ziran Kexue yu Gongcheng Jishu Ban)/
Journal of Tianjin University Science and Technology
ISSN (Online):0493-2137
E-Publication: Online Open Access
Vol: 59 Issue: 11:2026
DOI: 10.5281/zenodo.24412051

After initial seating, the Ti-base zirconia crown was positioned in a custom loading device, and a standardized vertical load of 15 N was applied to maintain uniform seating pressure during cementation procedure (Fig.30). And light polymerization was performed using an LED curing unit (Cicada LED Curing Light CV-215i Pro, Cicada Dental, China) with an output intensity of 1200 mW/cm² as specified by the manufacturer. While the Ti-base zirconia crown was maintained under load, the accessible buccal, lingual, mesial, and distal surfaces were light-cured for 20 seconds each at a distance of approximately 1 mm from the restoration. Excess resin cement was carefully removed using a dental explorer before final polymerization to remove residual cement around the margins and reduce the adverse effects on the peri-implant tissues. After removal from the loading device, final occlusal light curing was performed for 20 seconds. [3,15–17]



Figure 30: Custom Loading Device for Standardized Cementation

h) Delivery of Implant Zirconia Crowns

First, manual verification was performed by seating the crown and confirming passive adaptation without rocking or resistance. Radiographic verification was then carried out to confirm complete seating of the Ti-base/prosthetic assembly on the implant platform. The screw was initially hand tightened to check the stability of the connection without applying the final delivery torque. The seating of the prosthesis was also evaluated clinically, including assessment of occlusal contacts, proximal contacts, and the relationship of the restoration to the adjacent teeth and opposing dentition.

After confirming proper seating, the screw-retained zirconia crown was definitively tightened using a torque wrench according to the prosthetic torque recommended by the implant manufacturer, which was 30 Ncm. Applying the recommended torque is important to achieve adequate preload and reduce the risk of screw loosening during function. Following final torque application, the screw access channel was covered with a small piece of polytetrafluoroethylene (PTFE) tape and then sealed with a layer of composite resin. Finally, occlusion was adjusted according to implant-protected occlusal principles,

Tianjin Daxue Xuebao (Ziran Kexue yu Gongcheng Jishu Ban)/
Journal of Tianjin University Science and Technology
ISSN (Online):0493-2137
E-Publication: Online Open Access
Vol: 59 Issue: 11:2026
DOI: 10.5281/zenodo.24412051

with emphasis on axial loading, controlled cusp inclination, avoidance of non-axial excursive overload, and reduction of overload risk in posterior implant restorations.[18]

X. Outcome measures and follow-up schedule

Follow-Up Timeline

Participants were recalled according to the pre-specified follow-up schedule: baseline evaluation at 1 week after cementation/delivery (T0), followed by assessments at 6 months (T1) and 12 months (T2). (Table 1).

Table 1: Outcome Measures and Follow-up Schedule

Phase	Baseline 1 week	6months	12months
Modified USPHS Criteria	X	X	X
The mPI score	X	X	X
The mSBI	X	X	X

a) Primary Outcome: Survival Rate of Screw-Retained Zirconia Crowns Using Modified USPHS Criteria

The primary outcome was evaluation the survival rate of screw-retained zirconia crowns using selected modified United States Public Health Service (USPHS) criteria. In the present study, the USPHS assessment was limited to two bonding-related parameters: decementation and marginal adaptation. Decementation was used to assess loss of retention or adhesive failure between the zirconia crown and Ti-base abutment, while marginal adaptation was used to evaluate the clinical integrity of the crown–abutment interface and detect marginal discrepancies over time. (Table 2).

Table 2: Selected modified USPHS Criteria for Clinical Evaluation

Modified USPHS Criteria	Alpha	Bravo	Charlie	Delta
Decementation	No decementation between crown and abutment			Decementation between crown and abutment
Marginal adaptation	No probe catches	Slight probe catches but no gap	Detectable gap without loss of retention	Gap with loss of function requiring replacement

The clinical assessment was performed using 5× magnification loupes and standard diagnostic instruments, including a dental mirror and explorer, to improve detection of marginal discrepancies and retention-related changes during follow-up visits.

b) Secondary Outcomes: Peri-Implant Biological Parameters

Peri-implant soft tissue health was monitored using:

- **Modified Plaque Index (mPI)** scoring (0–3).
- **Modified Sulcus Bleeding Index (mSBI)** scoring (0–3).

Tianjin Daxue Xuebao (Ziran Kexue yu Gongcheng Jishu Ban)/
Journal of Tianjin University Science and Technology
ISSN (Online):0493-2137
E-Publication: Online Open Access
Vol: 59 Issue: 11:2026
DOI: 10.5281/zenodo.24412051

This system distinguishes between plaque that can only be detected through probing and plaque that is visible, as well as between isolated bleeding points and more extensive or continuous bleeding. To enhance reliability, measurements were taken at six standardized locations around each implant using a gentle probing force and a consistent method. [11]

The mPI was scored from 0 to 3, as follows

0: No plaque detected.

1: Plaque detected only by running a periodontal probe across the smooth marginal surface of the implant/crown; not visible to the naked eye.

2: Plaque visible to the naked eye.

3: Abundant soft plaque accumulation around the implant/crown margin and/or restoration.

The mSBI was scored from 0 to 3, as follows

0: No bleeding when a periodontal probe is passed along the peri- implant soft tissue.

1: Isolated bleeding spots visible.

2: Blood forms a confluent red line on the margin.

3: Heavy or profuse bleeding

X. Statistical analysis:

Statistical analysis was performed with SPSS 27®, Graph Pad Prism® and Microsoft Excel 2016. All data were presented as frequency and percentages. All comparisons were performed by using Chi square test and Fishers Exact test. The significant level was set to be at $P \leq 0.05$.

RESULT

All enrolled patients (n = 27) completed the entire follow-up period without any dropouts. Each participant attended all scheduled visits, and all clinical and biological evaluations, including Decementation, Marginal Adaptation, Modified Plaque Index (mPI), and Modified Sulcus Bleeding Index (mSBI), were successfully recorded at each time point.

I. Comparison between Groups

1. T0 baseline (1 week after crown cementation):

At baseline (T0), all evaluated crowns in Groups I, II, and III demonstrated ideal clinical performance with no recorded complications (Fig. 31).

For decementation and marginal adaptation (USPHS criteria), 100% of samples in all groups were classified as Alpha, with no Delta, bravo or charlie scores reported. Similarly, all participants in the three groups exhibited Score 0 for both modified Plaque Index (mPI)

Tianjin Daxue Xuebao (Ziran Kexue yu Gongcheng Jishu Ban)/
Journal of Tianjin University Science and Technology
ISSN (Online):0493-2137
E-Publication: Online Open Access
Vol: 59 Issue: 11:2026
DOI: 10.5281/zenodo.24412051

and modified Sulcular Bleeding Index (mSBI), indicating absence of plaque accumulation and gingival inflammation one week after crown delivery.

These findings confirm that all groups started from the same optimal clinical baseline conditions before subsequent follow-up assessments.

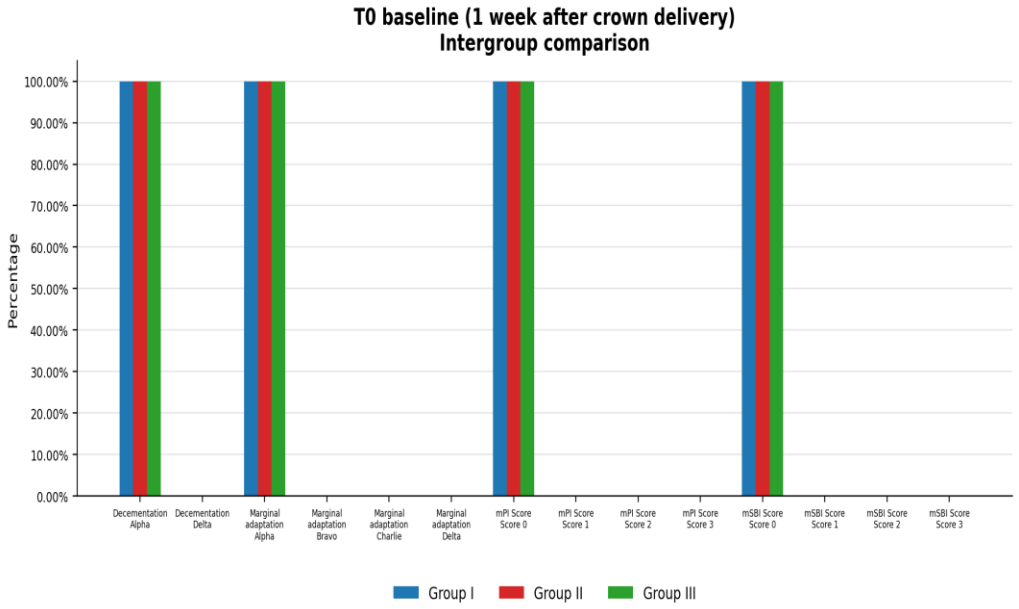

Figure (31): Bar Chart Showing Comparison between Groups Regarding Modified USPHS Outcomes (Decementation and Marginal Adaptation), Mpi Score, and Msbi Score at T0 Baseline (1 Week after Crown Delivery)

2. T1 (after 6 months)

After 6 months, statistically significant differences were observed among the three groups regarding decementation, modified Plaque Index (mPI), and modified Sulcular Bleeding Index (mSBI) scores (P = 0.003, 0.002, and 0.002, respectively) (Fig. 32).

For decementation (USPHS criteria), Group III demonstrated the best clinical performance, with 100% of crowns remaining Alpha and no cases of decementation, followed by Group II with 88.9% Alpha and 11.1% Delta scores. In contrast, Group I showed the poorest outcome, with only 33.3% Alpha and 66.7% Delta scores, indicating the highest incidence of decementation.

Regarding marginal adaptation, Group III demonstrated the most favorable marginal integrity, with 100% of crowns scored as Alpha and no Bravo, Charlie, or Delta scores. Group II followed with 88.9% Alpha and 11.1% Bravo scores, while Group I showed the least favorable marginal adaptation, with 66.7% Alpha and 33.3% Bravo scores. No Charlie or Delta scores were recorded in any group at T1. Although Group III showed the highest percentage of ideal marginal adaptation, the intergroup difference was not statistically significant (P = 0.28).

Tianjin Daxue Xuebao (Ziran Kexue yu Gongcheng Jishu Ban)/
Journal of Tianjin University Science and Technology
ISSN (Online):0493-2137
E-Publication: Online Open Access
Vol: 59 Issue: 11:2026
DOI: 10.5281/zenodo.24412051

Regarding plaque accumulation, as measured by modified plaque index (mPI), Group III exhibited the most favorable oral hygiene status, with 88.9% of cases maintaining Score 0, while Group II showed moderate performance with 55.6% Score 0 and 44.4% Score 1. Group I presented the least favorable results, with no Score 0 cases, 66.7% Score 1, and 33.3% Score 2.

Similarly, gingival health, assessed using the Modified Sulcus Bleeding Index (mSBI), Group III achieved the best outcomes, with 88.9% Score 0 and only 11.1% Score 1. Group II showed acceptable gingival health, with 66.7% Score 0 and 33.3% Score 1, whereas Group I recorded the highest gingival inflammation, with 77.8% Score 1 and 22.2% Score 2. Overall, Group III demonstrated superior clinical, periodontal, and prosthetic performance after 6 months, followed by Group II, while Group I showed the least favorable outcomes.

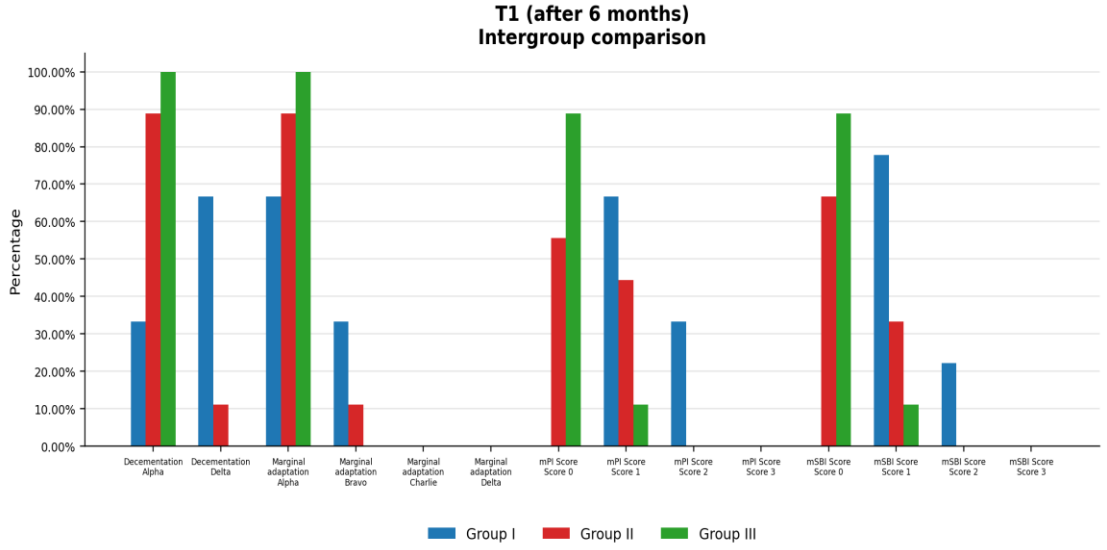

Figure 32: Bar Chart Showing Comparison between Groups Regarding Modified USPHS Outcomes (Decementation and Marginal Adaptation), Mpi Score, and Msbi Score at T1 (After 6 Months)

3. T2 (after 12 months)

At the 12-month follow-up (T2), statistically significant differences were detected among the three groups for decementation (USPHS), modified Plaque Index (mPI), and modified Sulcular Bleeding Index (mSBI) scores (P = 0.014, 0.001, and <0.0001, respectively) (Fig. 33).

For decementation, Group III maintained the highest clinical success, with 88.9% of crowns rated Alpha and only 11.1% Delta scores, indicating the lowest decementation incidence. Group II showed intermediate performance, with 66.7% Alpha and 33.3% Delta scores, while Group I demonstrated the poorest retention, with only 22.2% Alpha and 77.8% Delta scores.

Tianjin Daxue Xuebao (Ziran Kexue yu Gongcheng Jishu Ban)/
Journal of Tianjin University Science and Technology
ISSN (Online):0493-2137
E-Publication: Online Open Access
Vol: 59 Issue: 11:2026
DOI: 10.5281/zenodo.24412051

Regarding marginal adaptation, Group III showed the most favorable marginal integrity after 12 months, with 88.9% Alpha and 11.1% Bravo scores, with no Charlie or Delta scores. Group II showed intermediate performance, with 77.8% Alpha and 22.2% Bravo scores, while Group I demonstrated the least favorable marginal adaptation, with 44.4% Alpha, 44.4% Bravo, and 11.1% Charlie scores. No Delta scores were recorded for marginal adaptation in any group. Although Group III maintained the highest percentage of ideal marginal adaptation, the difference among groups was not statistically significant (P = 0.211). Regarding plaque accumulation, as measured by modified plaque index(mPI), Group III continued to exhibit the best oral hygiene outcomes, with 77.8% of participants maintaining Score 0 and only 22.2% Score 1. Group II showed moderate plaque control, with 33.3% Score 0 and 66.7% Score 1. In contrast, Group I presented the least favorable plaque status, with no Score 0 cases, 33.3% Score 1, 55.6% Score 2, and 11.1% Score 3, reflecting progressive plaque accumulation over time. For gingival health, assessed using the Modified Sulcus Bleeding Index (mSBI), Group III again showed superior periodontal condition, with 77.8% Score 0 and 22.2% Score 1. Group II demonstrated acceptable gingival status, with 44.4% Score 0 and 55.6% Score 1. Conversely, Group I showed the greatest gingival inflammation, with no Score 0 cases, 33.3% Score 1, and 66.7% Score 2. Overall, after 12 months, Group III consistently demonstrated the best prosthetic retention, plaque control, and gingival health, followed by Group II, whereas Group I exhibited the least favorable clinical and periodontal outcomes, indicating greater deterioration over time.

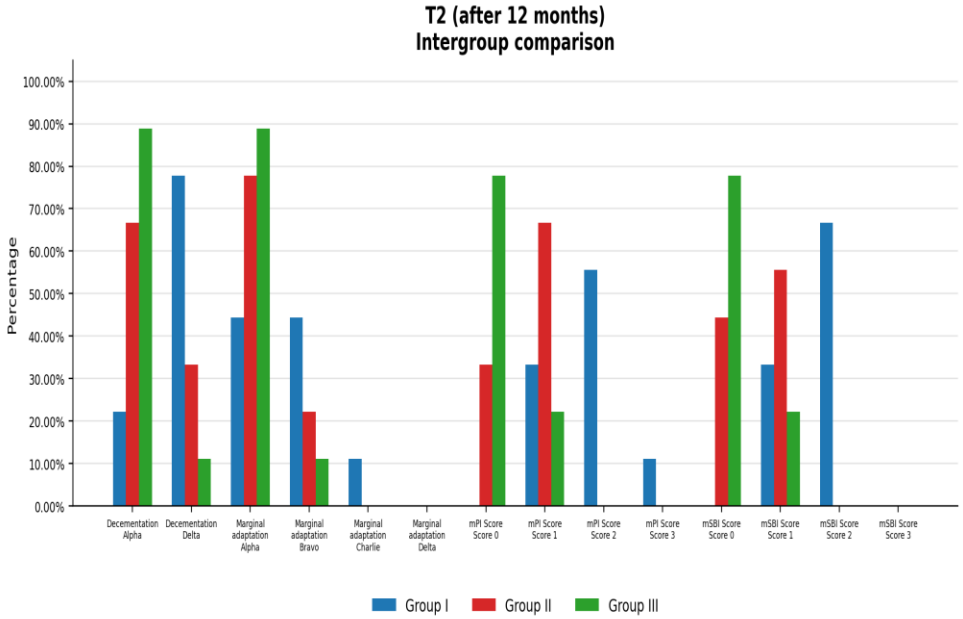

Figure 33: Bar Chart Showing Comparison between Groups Regarding Modified USPHS Outcomes (Decementation And Marginal Adaptation), MPI Score, And MSBI Score At T2 (After 12 Months*)*

Tianjin Daxue Xuebao (Ziran Kexue yu Gongcheng Jishu Ban)/
Journal of Tianjin University Science and Technology
ISSN (Online):0493-2137
E-Publication: Online Open Access
Vol: 59 Issue: 11:2026
DOI: 10.5281/zenodo.24412051

II. Effect of Time within Each Group

1. Group I

Within Group I, statistically significant changes were observed over time in decementation (USPHS), modified Plaque Index (mPI), and modified Sulcular Bleeding Index (mSBI) scores from baseline (T0) to 6 months (T1) and 12 months (T2) (P = 0.002, <0.0001, and <0.0001, respectively) (Fig. 34).

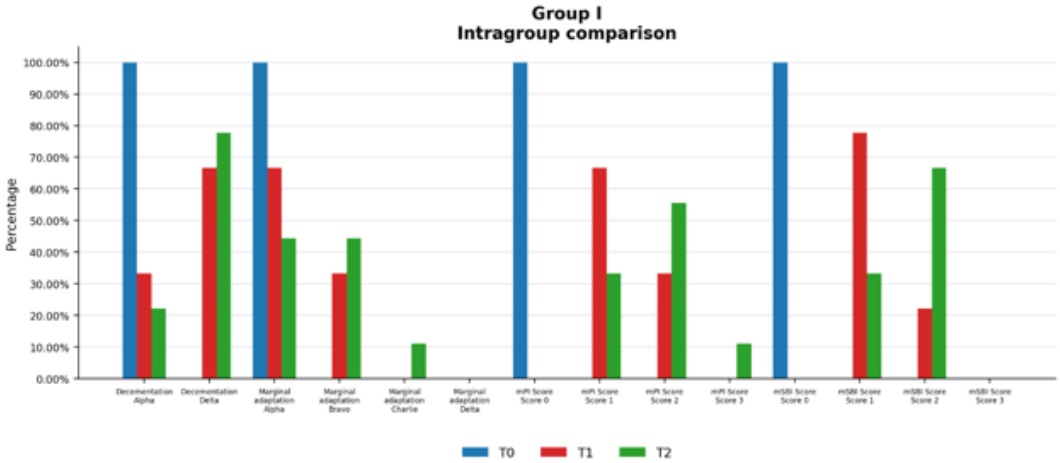

Figure 34: Bar Chart Showing Comparison between T0, T1, and T2 Regarding Modified USPHS Outcomes (Decementation and Marginal Adaptation), Mpi Score, and Msbi Score Within Group I

For decementation, all crowns initially demonstrated ideal retention at T0, with 100% Alpha scores. However, a marked decline was noted at T1, where Alpha scores decreased to 33.3% and Delta scores increased to 66.7%. This deterioration progressed further by T2, with only 22.2% Alpha scores and 77.8% Delta scores, indicating a substantial reduction in crown retention over time.

Regarding marginal adaptation, Group I showed progressive deterioration in marginal integrity throughout the follow-up period. All crowns were scored as Alpha at baseline (T0), indicating ideal marginal adaptation. At T1, Alpha scores decreased to 66.7%, while Bravo scores increased to 33.3%. By T2, further deterioration was observed, with only 44.4% Alpha scores, 44.4% Bravo scores, and 11.1% Charlie scores. No Delta scores were recorded for marginal adaptation. These changes reached the threshold of statistical significance (P = 0.05), indicating a significant decline in marginal integrity over time.

Regarding plaque accumulation, as measured by modified plaque index(mPI), all participants presented Score 0 at baseline, reflecting excellent oral hygiene. At T1, plaque levels worsened considerably, with 66.7% Score 1 and 33.3% Score 2. By T2, further deterioration was observed, with 55.6% Score 2 and 11.1% Score 3, indicating progressive plaque accumulation throughout the follow-up period.

Tianjin Daxue Xuebao (Ziran Kexue yu Gongcheng Jishu Ban)/
Journal of Tianjin University Science and Technology
ISSN (Online):0493-2137
E-Publication: Online Open Access
Vol: 59 Issue: 11:2026
DOI: 10.5281/zenodo.24412051

Similarly, gingival health measured using modified sulcus bleeding index (mSBI) significantly worsened over time. At baseline, all participants showed Score 0, indicating healthy gingival tissues. At T1, 77.8% of cases shifted to Score 1 and 22.2% to Score 2, while at T2, gingival inflammation became more pronounced, with 66.7% Score 2 and 33.3%

Score 1.

Overall, Group I demonstrated significant progressive deterioration in crown retention, plaque control, and gingival health from baseline to 12 months, suggesting that this group exhibited the least favorable long-term clinical and periodontal performance.

2. Group II

Within Group II, changes over time from baseline (T0) to 6 months (T1) and 12 months (T2) revealed no statistically significant difference in decementation (USPHS) scores ($P = 0.28$), while statistically significant differences were observed for modified Plaque Index (mPI) and modified Sulcular Bleeding Index (mSBI) scores ($P = 0.01$ and 0.04, respectively) (Fig. 35).

For decementation, all crowns demonstrated ideal retention at baseline, with 100% Alpha scores. Although Alpha scores decreased slightly over time to 88.9% at T1 and 66.7% at T2, with corresponding increases in Delta scores, these changes were not statistically significant, suggesting relatively stable crown retention throughout the 12-month follow-up period.

Regarding marginal adaptation, all crowns showed ideal marginal integrity at baseline, with 100% Alpha scores. At T1, Alpha scores slightly decreased to 88.9%, while Bravo scores increased to 11.1%. By T2, Alpha scores decreased further to 77.8%, with 22.2% Bravo scores. No Charlie or Delta scores were recorded throughout the follow-up period. These changes were not statistically significant ($P = 0.75$), indicating relatively stable marginal adaptation over 12 months.

Regarding plaque accumulation (mPI), all participants initially showed Score 0 at baseline. At T1, oral hygiene declined moderately, with 55.6% maintaining Score 0 and 44.4% shifting to Score 1. By T2, further deterioration was noted, with Score 0 decreasing to 33.3% and Score 1 increasing to 66.7%, indicating a gradual increase in plaque accumulation over time despite the absence of severe plaque scores.

Similarly, gingival health (mSBI) significantly changed across the follow-up period. At baseline, all participants exhibited Score 0. At T1, 66.7% retained Score 0 while 33.3% shifted to Score 1. By T2, gingival health showed additional decline, with 44.4% Score 0 and 55.6% Score 1, reflecting mild but progressive gingival inflammation over time.

Overall, Group II demonstrated relatively stable decementation performance over 12 months, while plaque accumulation and gingival health showed significant but gradual deterioration, remaining within mild clinical levels and indicating better long-term outcomes than Group I.

Tianjin Daxue Xuebao (Ziran Kexue yu Gongcheng Jishu Ban)/
Journal of Tianjin University Science and Technology
ISSN (Online):0493-2137
E-Publication: Online Open Access
Vol: 59 Issue: 11:2026
DOI: 10.5281/zenodo.24412051

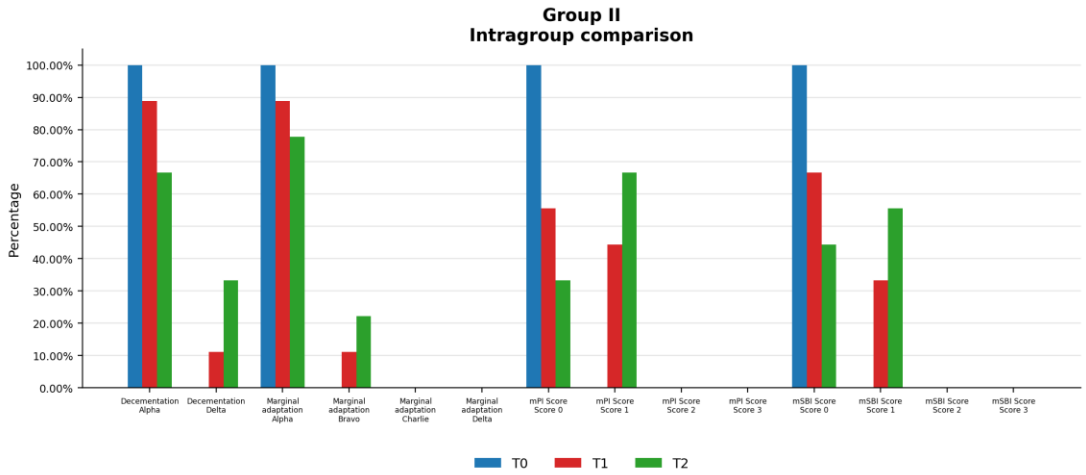

Figure 35: Bar Chart Showing Comparison between T0, T1, and T2 Regarding Modified USPHS Outcomes (Decementation and Marginal Adaptation), MPI Score, and MSBI Score Within Group II

3. Group III

Within Group III, no statistically significant differences were observed across the three time points (T0, T1, and T2) for decementation USPHS, mPI score, or mSBI score (Fig. 36).

For decementation (USPHS criteria), all subjects (100%) were classified as Alpha at T0 and T1. At T2, a slight reduction in Alpha ratings was observed (88.9%), with one case (11.1%) classified as Delta. However, this change was not statistically significant (P = 0.99), indicating overall stability of cement retention across the study period.

Regarding marginal adaptation, all crowns demonstrated ideal marginal integrity at T0 and T1, with 100% Alpha scores recorded at both time points. At T2, a slight reduction in Alpha scores was observed, with 88.9% of crowns remaining Alpha and only one crown (11.1%) shifting to Bravo. No Charlie or Delta scores were recorded throughout the follow-up period. This change was not statistically significant (P = 0.99), indicating stable marginal adaptation over 12 months.

Regarding mPI scores, the majority of participants maintained Score 0 at all time points, although a slight shift toward Score 1 was noted over time (from 0% at T0 to 22.2% at T2). Despite this trend, the difference was not statistically significant (P = 0.75).

A similar pattern was observed for mSBI scores, where most participants remained at Score 0, with a small increase in Score 1 at T1 and T2. No significant differences were found across time points (P = 0.75).

Tianjin Daxue Xuebao (Ziran Kexue yu Gongcheng Jishu Ban)/
Journal of Tianjin University Science and Technology
ISSN (Online):0493-2137
E-Publication: Online Open Access
Vol: 59 Issue: 11:2026
DOI: 10.5281/zenodo.24412051

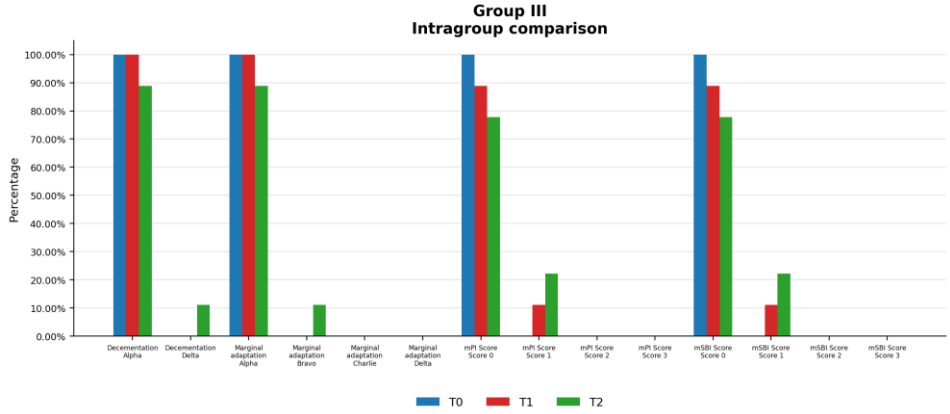

Figure 36: Bar Chart Showing Comparison between T0, T1, And T2 Regarding Modified USPHS Outcomes (Decementation and Marginal Adaptation), mPI Score, And MSBI Score within Group III

DISCUSSION

The present clinical trial investigated the effect of Ti-base surface treatment on survival rate and peri-implant biological outcomes of monolithic zirconia implant-supported crowns. Although Ti-base-supported CAD/CAM ceramic restorations have demonstrated favorable clinical outcomes, the stability of the ceramic–Ti-base interface remains a potential concern. Failure at this interface may result in complications such as debonding, marginal discrepancies, and movement between the bonded components, potentially affecting the long-term stability of the restoration.[19] Previous evidence has shown that the strength and stability of the ceramic–Ti-base interface are influenced by several factors, particularly the surface pretreatment of the Ti-base and the bonding protocol.[20]Accordingly, Ti-base surface conditioning was investigated as a potential factor affecting the clinical stability of CAD/CAM ceramic restorations bonded to titanium bases. Therefore, the present study compared untreated and surface-treated Ti-bases to determine whether modification of the titanium bonding surface influenced the clinical performance of screw-retained monolithic zirconia crowns in single mandibular first-molar implant restorations.

The null hypothesis was partially rejected. Ti-base surface treatment significantly affected decementation, whereas the intergroup difference in marginal adaptation was not statistically significant and therefore represents a favorable descriptive trend rather than evidence of a significant treatment effect. Significant intergroup differences were also observed for mPI and mSBI, demonstrating differences in peri-implant biological conditions among the treatment groups. Because the experimental modification was confined to the internal bonding surface, these biological findings should not be interpreted as a direct tissue response to the modified Ti-base surface. Rather, they may reflect differences in the overall clinical behavior of the restorations and factors such as restoration stability, marginal relationships, and cleansability that are relevant to peri-implant health.

Tianjin Daxue Xuebao (Ziran Kexue yu Gongcheng Jishu Ban)/
Journal of Tianjin University Science and Technology
ISSN (Online):0493-2137
E-Publication: Online Open Access
Vol: 59 Issue: 11:2026
DOI: 10.5281/zenodo.24412051

Radiographic assessment was combined with digital planning to evaluate implant-site suitability and establish a standardized, prosthetically driven implant position. Initial radiographs were used for preliminary assessment of the edentulous site, while CBCT provided three-dimensional information on available bone dimensions and the relationship of the proposed implant site to adjacent anatomical structures. The CBCT-derived DICOM data were subsequently integrated with intraoral-scan STL files, allowing the implant position and surgical guide to be planned according to the intended prosthetic restoration. This integrated workflow is consistent with that reported in a recent prospective study of posterior single-tooth implant restorations, in which CBCT acquisition, intraoral scanning, DICOM–STL superimposition, prosthetically driven planning, and guided implant placement were combined.[21] Similarly, **Chen et al., (2025)** [22] reported that integrating intraoral digital models with CBCT data facilitates individualized prosthetically driven treatment planning and accurate implant positioning, while potentially reducing planning errors and associated clinical risks. Therefore, the integrated digital workflow used in the present study provided a standardized approach to prosthetically driven implant planning and guided placement, with implant position determined in relation to the planned final restoration.

Extraoral bonding of the zirconia crown to the Ti-base was selected to provide greater control over cement application, crown seating, inspection of the bonded interface, and removal of excess cement before intraoral insertion. This approach combines the retrievability of a screw-retained restoration with the advantage of performing the adhesive procedure outside the oral cavity, where cement application and excess removal can be more effectively controlled.[20] This consideration is clinically relevant because residual submucosal cement associated with intraoral cementation has been linked to peri-implant inflammatory complications. Supporting this concern, **Montevecchi et al., (2025)** [23] detected residual cement in 80.4% of patients presenting with peri-implant disease around cement-retained restorations and reported that the remnants were located significantly more apically in peri-implantitis than in mucositis. Therefore, the extraoral bonding protocol adopted in the present study minimized the possibility of leaving cement remnants adjacent to the peri-implant tissues and reduced cement-related biological interference during follow-up.

Tribochemical silica coating was selected as the mechanical surface-conditioning protocol because modifying the titanium surface may improve the stability of the zirconia–Ti-base bonded interface. This approach is supported by a recent study, which reported that Tribochemical silica coating produced the highest bond strength among the tested surface treatments when zirconia crowns were bonded to titanium abutments. [24] The addition of an MDP-containing primer was intended to investigate whether combining mechanical surface modification with a chemical bonding mechanism could provide an additional benefit at the zirconia–Ti-base interface. MDP-containing primers can interact with metal-oxide surfaces and have been reported to enhance resin bonding to titanium and zirconia; however, their effectiveness may vary depending on the substrate, surface pretreatment, and luting protocol.[20] Accordingly, the present study included three Ti-base surface conditions: an untreated surface, Tribochemical silica coating alone, and

Tianjin Daxue Xuebao (Ziran Kexue yu Gongcheng Jishu Ban)/
Journal of Tianjin University Science and Technology
ISSN (Online):0493-2137
E-Publication: Online Open Access
Vol: 59 Issue: 11:2026
DOI: 10.5281/zenodo.24412051

Tribochemical silica coating followed by application of an MDP-containing primer. This design allowed the clinical effect of mechanical surface conditioning to be evaluated and determined whether adding chemical pretreatment to the mechanically conditioned surface resulted in an additional clinical benefit.

In the present study, Tribochemical silica coating was applied only to the Ti-base bonding surface, whereas the transmucosal neck was left unmodified. This approach confined the experimental intervention to the zirconia–Ti-base bonding interface and avoided introducing a second surface-related variable at the peri-implant tissue interface. The potential influence of abutment surface characteristics on peri-implant soft-tissue health has been investigated in systematic reviews by **Sanz-Martín et al., (2018)** [25] , and **Canullo et al., (2020)** [26], which evaluated outcomes related to inflammation, plaque accumulation, and bleeding. Although the available evidence does not demonstrate a consistent clinically significant effect of abutment surface topography or modification on peri-implant inflammatory outcomes, differences in the transmucosal surface could still represent a potential source of biological variability. Therefore, maintaining an identical, unmodified transmucosal surface across all treatment groups helped minimize potential confounding and allowed differences in mPI and mSBI to be interpreted primarily in relation to the investigated Ti-base bonding-surface treatments.

The cementation protocol was standardized across all treatment groups to minimize technique-related variability and ensure that any differences in clinical outcomes could be attributed primarily to the investigated Ti-base surface treatments rather than to variations in the bonding procedure. A self-adhesive resin cement was selected to provide adequate polymerization even in areas where light transmission through the zirconia may be limited by the thickness and geometry of the restoration. In addition, a standardized seating pressure was applied to promote consistent seating of the zirconia crown on the Ti-base and minimize variations in cement film thickness. Previous studies have shown that polymerization conditions, cement thickness, and seating force can influence the marginal adaptation and bonding performance of zirconia–Ti-base restorations.[15–17,27] Therefore, maintaining an identical cementation protocol across all groups helped control potential bonding-related confounding factors and allowed a more reliable comparison of decementation and marginal adaptation among the different Ti-base surface-treatment protocols.

At 12 months, decementation showed the clearest difference among groups. The proportion of restorations maintaining Alpha scores was highest in Group III (tribochemical silica coating plus an MDP-containing primer; 88.9%), followed by Group II (tribochemical silica coating alone; 66.7%) and Group I (untreated Ti-base; 22.2%), with a statistically significant intergroup difference. This pattern is consistent with **Pitta et al., (2021)** [4] who reported bonding failure in 73.3% of untreated specimens, compared with 40% after CoJet treatment and 6.7% after 50-µm alumina abrasion ($P < 0.05$). **Wan et al., (2025)** [6] also found greater pull-out forces when an MDP-containing primer was used, alone or with airborne-particle abrasion. However, laboratory bonding failure and pull-out force are not directly equivalent to clinical decementation. The findings of **Kemarly et al.,**

Tianjin Daxue Xuebao (Ziran Kexue yu Gongcheng Jishu Ban)/
Journal of Tianjin University Science and Technology
ISSN (Online):0493-2137
E-Publication: Online Open Access
Vol: 59 Issue: 11:2026
DOI: 10.5281/zenodo.24412051

(2020) [5] further indicate that the benefit of chemical pretreatment depends on the bonding agent and protocol used. Therefore, the favorable outcome in Group III should be attributed to the specific combination tested rather than generalized to all primers or bonding systems.

Marginal adaptation followed a numerically favorable pattern in the treated groups, with Group III showing the highest proportion of Alpha scores, followed by Group II and then Group I. However, the intergroup difference was not statistically significant (P = 0.211), so the results do not demonstrate a significant treatment effect on marginal adaptation. Unlike decementation, marginal adaptation is influenced by several factors, including restoration design, digital acquisition, CAD/CAM fabrication, cement space, fit at the zirconia–Ti-base interface, and cementation. Previous studies have reported clinically acceptable marginal adaptation for different zirconia–Ti-base configurations[9,10] The observed trend should therefore be interpreted descriptively rather than as proof that surface treatment improved marginal adaptation.

At 12 months, Group III showed the lowest mPI and mSBI scores, followed by Group II, while Group I had the least favorable biological outcomes; differences among groups were statistically significant for both indices. These findings are consistent with evidence linking plaque accumulation to peri-implant mucosal bleeding. **De Tapia et al., (2022)** [28] reported an association between implant-level plaque and mucosal bleeding, while **Heitz-Mayfield., (2024)** [29] identified biofilm as a principal etiological factor in peri-implant mucositis and bleeding on probing as an important clinical indicator. In this trial, however, surface conditioning was limited to the internal Ti-base bonding surface and the transmucosal portion remained identical across groups. Thus, the biological findings cannot be attributed to direct tissue contact with the modified surface. They indicate an association with treatment group, but do not establish a direct causal pathway; possible indirect influences include restoration stability, marginal relationships, contour, and cleansability.

Longitudinal results further distinguished the groups. In Group I, the proportion of Alpha scores for decementation decreased from 100% at baseline to 33.3% at six months and 22.2% at 12 months (P = 0.002). Marginal-adaptation Alpha scores decreased from 100% to 66.7% and 44.4%, respectively (P = 0.05), while mPI and mSBI deteriorated significantly over time (both P < 0.0001). The clinical decementation reported by **Saponaro et al., (2023)** [30] similarly highlights failure at the zirconia–Ti-base interface as a relevant complication during service. In Group II, decementation Alpha scores were 100%, 88.9%, and 66.7% at baseline, six months, and 12 months, respectively, but the change was not significant (P = 0.28); marginal adaptation also remained statistically stable (P = 0.75). In contrast, mPI and mSBI changed significantly over time (P = 0.01 and P = 0.04, respectively). These findings are consistent with the lower bonding-failure rate after CoJet treatment reported by **Pitta et al., (2021)** [4] .

Group III showed no statistically significant changes over the 12-month follow-up in decementation or marginal adaptation (P = 0.99 for both), or in mPI and mSBI (P = 0.75 for both). This longitudinal stability was consistent with its most favorable 12-month

Tianjin Daxue Xuebao (Ziran Kexue yu Gongcheng Jishu Ban)/
Journal of Tianjin University Science and Technology
ISSN (Online):0493-2137
E-Publication: Online Open Access
Vol: 59 Issue: 11:2026
DOI: 10.5281/zenodo.24412051

profile. **Wan et al., (2025)** [6] reported increased pull-out forces with an MDP-containing primer, including in combination with airborne-particle abrasion, providing complementary laboratory support for the potential contribution of chemical conditioning. Taken together, the intergroup and longitudinal findings show a consistent clinical pattern: the untreated group deteriorated most, tribochemical silica coating alone showed an intermediate outcome, and the combined protocol showed the most favorable overall profile, particularly for decementation.

CONCLUSION

Based on the constraints of this 12-month randomized controlled trial, the following conclusions can be made:

1) Monolithic zirconia crowns showed favorable clinical performance in posterior screw-retained implant restorations when the bonding and occlusal protocols were carefully standardized.
2) The untreated Ti-base group showed the highest decementation rate after 12 months, indicating that absence of Ti-base surface treatment may compromise retention in posterior implant restorations.
3) Tribochemical silica coating alone or combined with MDP containing primer reduced the decementation rate compared with no surface treatment.
4) Tribochemical silica coating followed by Z-Prime Plus demonstrated the lowest observed decementation rate. Although marginal adaptation was numerically more favorable, the intergroup difference was not statistically significant.
5) The peri-implant biological parameters, mPI and mSBI, showed more favorable trends in the surface-treated groups.

Overall, the findings support the clinical importance of standardized Ti-base surface treatment protocols for improving the performance of screw-retained zirconia crowns in posterior mandibular implant restorations.

References

1) Al-Thobity, A. M. Titanium Base Abutments in Implant Prosthodontics: A Literature Review. Eur. J. Dent. 2022, 16 (1), 49–55.
2) Tajti, P.; Solyom, E.; Czumbel, L. M.; Szabó, B.; Fazekas, R.; Németh, O.; Hermann, P.; Gerber, G.; Hegyi, P.; Mikulás, K. Monolithic Zirconia as a Valid Alternative to Metal-Ceramic for Implant-Supported Single Crowns in the Posterior Region: A Systematic Review and Meta-Analysis of Randomized Controlled Trials. Journal of Prosthetic Dentistry. Elsevier Inc. November 1, 2024, pp 881–889.
3) Krongvanitchayakul, R.; Kunavisarut, C. Retention of Zirconia Crown to Oxidized Titanium Base Abutment: Experimental Research. PLoS One 2023, 18 (10), e0287108.
4) Pitta, J.; Burkhardt, F.; Mekki, M.; Fehmer, V.; Mojon, P.; Sailer, I. Effect of Airborne-Particle Abrasion of a Titanium Base Abutment on the Stability of the Bonded Interface and Retention Forces of Crowns after Artificial Aging. Journal of Prosthetic Dentistry 2021, 126 (2), 214–221.

Tianjin Daxue Xuebao (Ziran Kexue yu Gongcheng Jishu Ban)/
Journal of Tianjin University Science and Technology
ISSN (Online):0493-2137
E-Publication: Online Open Access
Vol: 59 Issue: 11:2026
DOI: 10.5281/zenodo.24412051

5) Kemarly, K.; Arnason, S. C.; Parke, A.; Lien, W.; Vandewalle, K. S. Effect of Various Surface Treatments on Ti-Base Coping Retention. Oper. Dent. 2020, 45 (4), 426–434.

6) Wan, Q.; Lee, D.-H.; Kim, R. J. Y.; Yeo, I.-S. L.; Lee, J.-H.; Sailer, I. Pull-out Force and Fracture Load of Fully Sintered Zirconia Hybrid Abutment-Crowns on Ti-Base Abutments: Surface Treatment Effects and Material Comparison. J. Dent. 2025, 163, 106134.

7) Zahoui, A.; Bergamo, E.; Marun, M.; Silva, K.; Coelho, P.; Bonfante, E. Cementation Protocol for Bonding Zirconia Crowns to Titanium Base CAD/CAM Abutments. Int. J. Prosthodont. 2020, 33 (5), 527–535.

8) Alsabeeha, N. H. M.; Amir-Rad, F.; Ma, S.; Shah, M.; Hannawi, H.; Tawse-Smith, A.; Duncan, W. J.; Baqain, Z. H.; Atieh, M. A. Monolithic Zirconia Single Crowns Supported by Narrow or Standard Diameter Titanium-Zirconium Implants in Posterior Sites: One-Year Results of a Randomized Controlled Trial. Int. J. Oral Maxillofac. Implants 2024, 1–23.

9) Fakhr, M. W. Z. F.; Alansary, H.; Hassanien, E. E. Y. Internal Fit and Marginal Adaptation of All-Ceramic Implant-Supported Hybrid Abutment Crowns with Custom-Milled Screw-Channels on Titanium-Base: In-Vitro Study. BMC Oral Health 2024, 24 (1), 1073.

10) Sasany, R.; Uçar, S. M.; Yilmaz, B. Assessment of Fit Accuracy and Retentive Strength of Additively Manufactured Zirconia Crowns Luted to Ti-base Abutments with Different Resin Cements: An in Vitro Study. Journal of Prosthodontics 2025.

11) Heitz-Mayfield, L. J. A.; Salvi, G. E. Peri-Implant Mucositis. J. Clin. Periodontol. 2018, 45, S237–S245.

12) Misch CE, Judy KW.Classification of Partially Edentulous Arches for Implant Dentistry. Int. J. Oral Implantol. 1987.

13) Derakhshani, A.-J.; Beuer, F.; Böse, M. W. H.; Herklotz, I.; Unkovskiy, A. 3D Analysis of Soft Tissue Dimensional Changes after Dental Implant Placement with Butt-Joint vs. Conical Connection: A 12-Month Randomized Control Trial. Int. J. Implant Dent. 2024, 10 (1).

14) Nagaoka, N.; Yoshihara, K.; Feitosa, V. P.; Tamada, Y.; Irie, M.; Yoshida, Y.; Van Meerbeek, B.; Hayakawa, S. Chemical Interaction Mechanism of 10-MDP with Zirconia. Sci. Rep. 2017, 7.

15) Ibrahim, E. A.; Khamis, M. M.; Ezzelarab, S.; Abdelhamid, A. M. Retention of Zirconia Crowns to Titanium Bases with Straight versus Angled Screw Access Channels: An Invitro Study. BMC Oral Health 2023, 23 (1).

16) Oddbratt, E.; Hua, L.; Chrcanovic, B. R.; Papia, E. Bond Strength of Zirconia- or Polymer-Based Copings Cemented on Implant-Supported Titanium Bases–an in Vitro Study. Biomater. Investig. Dent. 2021, 8 (1), 129–136.

17) Rohr, N.; Brunner, S.; Märtin, S.; Fischer, J. Influence of Cement Type and Ceramic Primer on Retention of Polymer-Infiltrated Ceramic Crowns to a One-Piece Zirconia Implant. Journal of Prosthetic Dentistry 2018, 119 (1), 138–145.

18) Yuan, J. C. C.; Sukotjo, C. Occlusion for Implant-Supported Fixed Dental Prostheses in Partially Edentulous Patients: A Literature Review and Current Concepts. J. Periodontal Implant Sci. 2013, 43 (2), 51–57.

19) Sorrentino, R.; Ruggiero, G.; Toska, E.; Leone, R.; Zarone, F. Clinical Evaluation of Cement-Retained Implant-Supported CAD/CAM Monolithic Zirconia Single Crowns in Posterior Areas: Results of a 6-Year Prospective Clinical Study. Prosthesis 2022, 4 (3), 383–393.

20) Shadid, R. M. Retention of CAD-CAM Implant-Supported Ceramic Restorations Luted to Titanium Bases: A Systematic Review of in-Vitro Studies. Clinical, Cosmetic and Investigational Dentistry. Dove Medical Press Ltd 2025, pp 305–333.

Tianjin Daxue Xuebao (Ziran Kexue yu Gongcheng Jishu Ban)/
Journal of Tianjin University Science and Technology
ISSN (Online):0493-2137
E-Publication: Online Open Access
Vol: 59 Issue: 11:2026
DOI: 10.5281/zenodo.24412051

21) Donker, V. J. J.; Raghoebar, G. M.; Jensen-Louwerse, C.; Vissink, A.; Meijer, H. J. A. Monolithic Zirconia Single Tooth Implant-Supported Restorations with CAD/CAM Titanium Abutments in the Posterior Region: A 1-Year Prospective Case Series Study. Clin. Implant Dent. Relat. Res. 2022, 24 (1), 125–132.

22) Chen, C. S.; Hsu, H.; Kuo, Y. W.; Kuo, H. Y.; Wang, C. W. Digital Workflow and Guided Surgery in Implant Therapy—Literature Review and Practical Tips to Optimize Precision. Clinical Implant Dentistry and Related Research. John Wiley and Sons Inc June 1, 2025.

23) Montevecchi, M.; Valeriani, L.; Salvadori, M. F.; Stefanini, M.; Zucchelli, G. Excess Cement and Peri-Implant Disease: A Cross-Sectional Clinical Endoscopic Study. J. Periodontol. 2025, 96 (9), 965–973.

24) Turker, N.; Özarslan, M.; Buyukkaplan, U.; Başar, E. Effect of Different Surface Treatments Applied to Short Zirconia and Titanium Abutments. Int. J. Oral Maxillofac. Implants 2020, 35 (5), 948–954.

25) Sanz-Martín, I.; Sanz-Sánchez, I.; Carrillo de Albornoz, A.; Figuero, E.; Sanz, M. Effects of Modified Abutment Characteristics on Peri-Implant Soft Tissue Health: A Systematic Review and Meta-Analysis. Clin. Oral Implants Res. 2018, 29 (1), 118–129.

26) Canullo, L.; Menini, M.; Santori, G.; Rakic, M.; Sculean, A.; Pesce, P. Titanium Abutment Surface Modifications and Peri-Implant Tissue Behavior: A Systematic Review and Meta-Analysis. Clinical Oral Investigations. Springer March 1, 2020, pp 1113–1124.

27) Anastasaki, A.; Bora, P.; Kourtis, S.; Fu, C. C. The Effect of Zirconia Material and the Height of the Ceramic Coping on the Strength of Hybrid Ti-Ceramic Abutments. Dent. J. (Basel). 2025, 13 (7).

28) de Tapia, B.; Bonnin, M.; Valles, C.; Mozas, C.; Herrera, D.; Sanz, M.; Nart, J. Clinical Outcomes and Associated Factors in the Treatment of Peri-Implant Mucositis, Combining Mechanical Debridement and Prosthesis Modification: A 30-Month Follow-up Prospective Case Series. J. Clin. Periodontol. 2022, 49 (12), 1357–1365.

29) Heitz-Mayfield, L. J. A. Peri-Implant Mucositis and Peri-Implantitis: Key Features and Differences. Br. Dent. J. 2024, 236 (10), 791–794.

30) Saponaro, P. C.; Karasan, D.; Donmez, M. B.; Johnston, W. M.; Yilmaz, B. Prosthetic Complications with Monolithic or Micro-Veneered Implant-Supported Zirconia Single-Unit, Multiple-Unit, and Complete-Arch Prostheses on Titanium Base Abutments: A Single Center Retrospective Study with Mean Follow-up Period of 72.35 Months. Clin. Implant Dent. Relat. Res. 2023, 25 (1), 99–106.